

Pleomorphic Adenoma of the Anterior Hard Palate: A Rare Case Report

Sushruth Nayak¹, Ramesh Ram Fry², Prachi Nayak³, Kush Pathak³, Asha Karadwal⁴

¹Professor & Head, Department of Oral Pathology & Microbiology, ²Professor, Department of Oral & Maxillofacial Surgery, ³Reader, ⁴Senior Lecturer, Department of Oral Pathology & Microbiology M.M. College of Dental Sciences and Research, M.M. (Deemed to be University), Mullana (Ambala), Haryana, India

Abstract

Pleomorphic adenoma (PA) is a benign tumor of the salivary glands that has components of both epithelial and mesenchymal origin. The most common site for the PA is the parotid or submandibular glands. On rare occasions, the tumor may arise from the minor salivary glands and present as an intraoral swelling over the hard palate or lip. But the anterior hard palate is not the commonest site for PA. We report the case of a 42-year old man who came with a complaint of a swelling in the anterior region of the hard palate and later diagnosed as pleomorphic adenoma based on histopathological examination.

Keywords: Pleomorphic adenoma, anterior hard palate, salivary gland.

Introduction

The pleomorphic adenoma (PA) accounts for 73% of all salivary gland tumors, the palate being the most preferred intraoral site (specifically, the junction of the soft and hard palates), followed by upper lip, buccal mucosa, floor of the mouth, tongue, tonsil, pharynx and retromolar area. PA contains elements of both epithelial and mesenchymal origin.¹ Occasionally it may arise from the minor salivary glands confined in the hard palate and other parts of oral mucosa.² Patients age most commonly range between the fifth and sixth decade of life. About 60% of the affected individuals are women.³ The tumor is usually a slow growing, painless and firm mass on palpation. Possible complications to treatment include the risk of recurrence and malignant transformation.⁴ In the literature there are very few published case reports

of pleomorphic adenoma in the anterior hard palate. So this is an interesting case of a 42-year old man who came with a complaint of a swelling in the anterior region of the hard palate. The lesion was excised surgically and the specimen was sent for histopathological examination which gave the confirmatory diagnosis of pleomorphic adenoma.

Case Report: A 42 year old male patient reported to the dental college with a chief complaint of swelling in the anterior region of the palate. The duration of the swelling was 2 to 3 months. On examination there was a 2.5 × 2.5 cm sized, circular lesion which was soft and compressible present in the left anterior palatal region in relation to 21,22 and 23. Tooth number 21 & 22 had undergone root canal treatment earlier. The swelling was fixed to the underlying structure without any change in the colour of the overlying mucosa (Figure 1). There was no regional lymphadenopathy seen. The radiograph showed the bony invasion. The clinical differential diagnosis of radicular cyst and adenomatoid odontogenic tumor was made. An excisional biopsy was done after taking the informed consent of the patient and the sample was sent for the histopathological examination.

Hematoxylin and Eosin stained tissue section revealed the presence of well circumscribed tissue composed of numerous salivary gland ducts. The

Corresponding Author:

Dr. Kush Pathak,

MDS, Reader, Department of Oral Pathology & Microbiology, M.M. College of Dental Sciences and Research, M.M (Deemed to be University), Mullana (Ambala)-133207, Haryana, India
e-mail: dr.kushpathak2011@gmail.com
Mobile No.: +91- 8239387376

connective tissue surrounding the ducts was myxomatous in appearance (Figure 2). The main cell population included ductal and myoepithelial type with other areas also showing plasmacytoid type of cells. The ductal lumen was filled with mucin (which was confirmed by special stain PAS) (Figure 3). Periphery of the lesion also showed prominent chondroid and osseous like areas (Figure 4). Overall features were diagnostic of pleomorphic adenoma.

Discussion

PA is the most common tumor of salivary glands.¹ The term pleomorphic describes the embryogenic origin of these tumors, which contains both epithelial and mesenchymal tissues.⁵ It has been postulated that these tumors arise from intercalated and myoepithelial cells.¹ Pleomorphic adenoma accounts for 50-70% of parotid tumors, 53-72% of submandibular tumors and 33-41% of minor salivary gland tumors.⁶ Most common intraoral location is the palate (specifically, the junction of the soft and hard palates), followed by upper lip, buccal mucosa, floor of the mouth, tongue, tonsil, pharynx and retromolar area. Palatal tumors are usually dome shaped mass with smooth-surface found on posterior lateral part of the palate.⁷ In the present case the swelling was located in the left anterior region of the hard palate. Usually the PA does not show the symptoms of pain, tenderness and ulceration. Although it is a benign tumor, the recurrence rate is high and few cases, have shown to transform into a malignant tumor.^{1,2} Differential diagnosis for the swellings in the palate includes palatal abscess, odontogenic cysts, fibroma, lipoma, neurofibroma, schwannoma, mucoepidermoid carcinoma and oral papilloma.^{8,9}

Tumors of the minor salivary glands show a variety of symptoms, depending upon the site. Such symptoms may include dysphagia, epistaxis and difficulty in mastication. The pleomorphic adenomas vary in their consistency which ranges from soft in cases of mucinous lesions to hard in cases where there is extensive chondroid or collagenous components.¹⁰ In the present case, the swelling was soft in consistency due to the excessive ductal proliferation along with mucin.

Histologically, pleomorphic adenoma shows a great variety in morphology. The mesenchymal components

may be myxoid, cartilaginous, osseous, or hyalinized. The myxoid stroma undergoes chondroid metaplasia to form prominent chondroid like areas. Long standing cases show increased hyalinization which is the characteristic feature of pleomorphic adenoma.¹¹

The treatment for PA includes complete surgical resection of the tumor with a surrounding adjacent normal tissue.^{1,2} PA of the minor salivary glands have low recurrence rate, while the recurrence rate of parotid gland is up to 44%.¹²

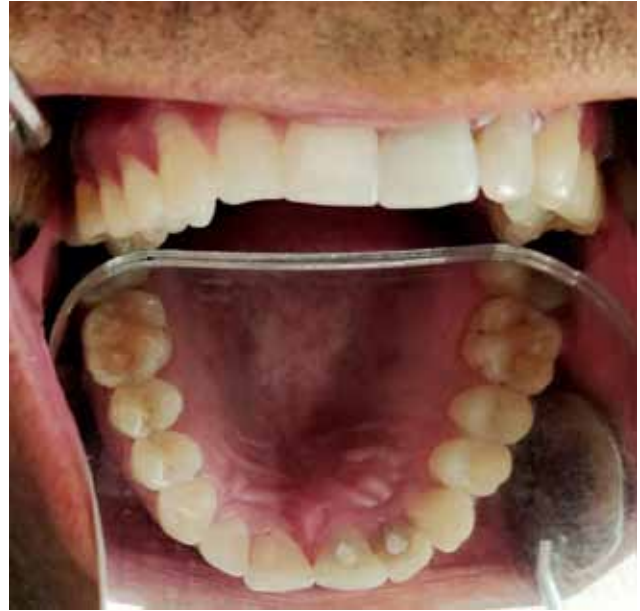

Figure 1: Swelling in the anterior part of the palate

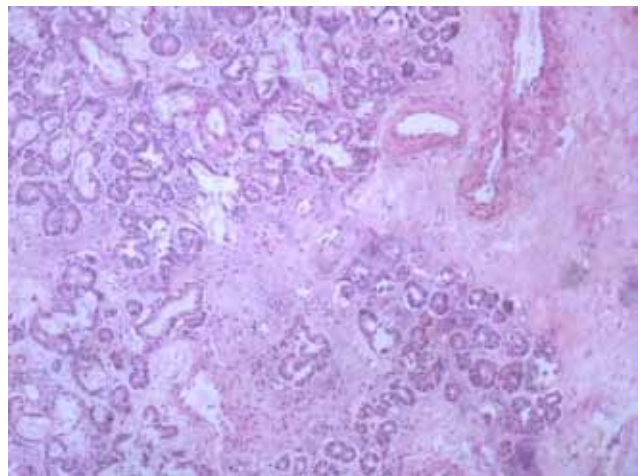


Figure 2: Section showing presence of numerous salivary gland ducts with myxomatous area (10x magnification)

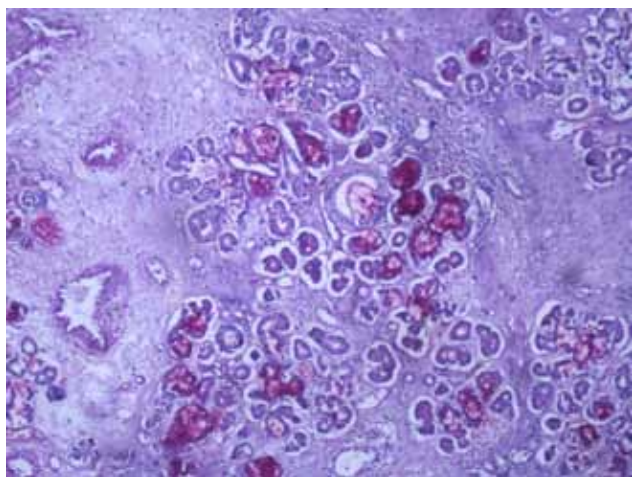


Figure 3: PAS staining showing the presence of mucin

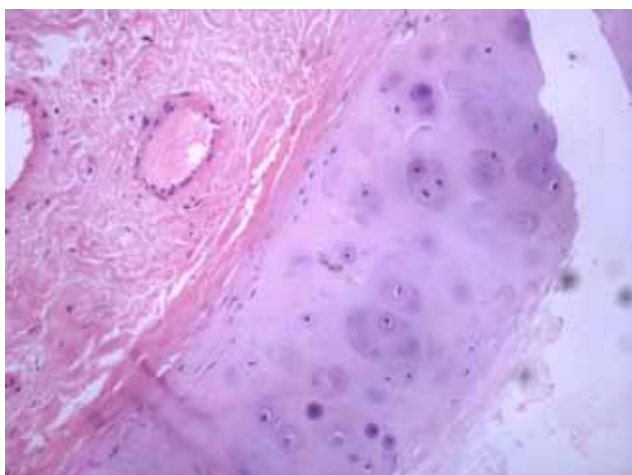


Figure 4: Prominent chondroid like areas (20x magnification)

Conclusion

The PA of the hard palate is a most common neoplasm of small salivary glands. Clinically it is very difficult to diagnose it and do proper treatment plans. A painless and a slow growing palatal mass can only be diagnosed by histopathological examination because of its different clinical diversity. Even in the present case clinical differential diagnosis of radicular cyst and adenomatoid odontogenic tumor was made which eventually turned out to be a pleomorphic adenoma histopathologically.

Ethical Clearance: Since it was a case report, there was no need for the ethical clearance from the committee.

Source of Funding: Nil

Conflict of Interest: Nil

References

1. Suen JY, Synderman NL. Benign neoplasms of the salivary glands. In: Cummings CW, Fredrickson JM, Harker LA, Krause CJ, Schuller DE, editors. *Otolaryngology—Head and Neck surgery*. 2. St. Louis: Mosby Year Book; 1993. pp. 1029–1042.
2. Feinmesser R, Gay I. Pleomorphic adenoma of the hard palate: an invasive tumour? *J Laryngol Otol*. 1983;97:1169–1171. doi: 10.1017/S002221510009616X.
3. Frazell EL. Clinical aspects of tumors of the major salivary glands. *Cancer* 1954;7:637-59.
4. Reiland MD, Koutlas IG, Gopalakrishnan R, Pearson AG, Basi DL. Metastasizing pleomorphic adenoma presents intraorally: A case report and review of the literature. *J Oral Maxillofac Surg* 2012;70:e531-40.
5. Batsakis JG (1981) Neoplasms of the minor and ‘lesser’ major salivary glands. In: *Tumors of the head and neck*. The Williams and Wilkins, Baltimore, pp 38–47.
6. Friedrich RE, Li L, Knop J, Giese M, Schmelzle R. Pleomorphic adenoma of the salivary glands: analysis of 94 patients. *Anticancer Res*. 2005; 25:1703-1705
7. Sreenivas DS. Pleomorphic adenoma of the palate: A case report. *J Indian Dent Assoc*. 2011; 5: 557–558.
8. Dhanuthai K, Sappayatosok K, Kongin K. Pleomorphic adenoma of the palate in a child: a case report. *Med Oral Patol Oral Cir Bucal*. 2009; 14:73–75.
9. Gupta M, Gupta M. Pleomorphic adenoma of the hard palate. *BMJ Case Rep*. 2013; 9: 1-2.
10. Daniels JS, Ali I, Al Bakri IM, Sumangala B. Pleomorphic adenoma of the palate in children and adolescents: A report of 2 cases and review of the literature. *J Oral Maxillofac Surg* 2007;65:541-9.
11. Margaritescu C, Raica M, Surpateanu M, Jaubert F, et al. Tumoral stroma of salivary pleomorphic adenoma – Histopathological, histochemical and immunohistochemical study. *Rom J Morphol Embryol* 2005;46:211-23.
12. Rahnama M, Orzędala-Koszel U, Czupkałło L, Lobacz M. Pleomorphic adenoma of the palate: a case report and review of the literature. *Contemp Oncol (Pozn)*. 2013; 17: 103-106.