

# Management of Oroantral Communication Using Double Layered Closure with Buccal Fat Pad and Buccal Advancement Flap: Prospective Randomized Clinical Study

**Kumar Nilesh**

*Prof and Head of Department, Dept. of Oral and Maxillofacial Surgery; School of Dental Sciences; Krishna Institute of Medical Sciences University; Karad*

## Abstract

**Introduction:** Although many techniques are available for management of oroantral communication, they utilize single layer tissue for closure of defect which is composite in nature. There is limited evidence in literature regarding efficacy of double layered closure using combination of flaps. This study was designed to assess utility of double layer closure of oroantral communication using buccal fat pad and buccal mucosa advancement flap.

**Material and Method:** Patients with oroantral communication were randomly allocated to two groups; group A were treated with two layered closure (buccal fat pad and buccal mucosa) and group B were treated with single layer closure (buccal fat pad). Same protocol of perioperative management was used for both groups. The postoperative parameters evaluated included success of surgery (complete closure without any nasal regurgitation), duration of surgery, pain, swelling and mouth opening.

**Results:** Total of 27 patients were divided into group A (n=13) and group B (n=14). The mean size of the defect was 28.23 mm in study group and 24.57 mm in the control group. The surgical procedure took more time (42.23 minutes) in group A, as compared to group B (26.21 minutes). Post-operative evaluation of pain and mouth opening showed no statistically significant between the two groups at 7th and 30th postoperative days respectively. However, swelling was relatively more when combination of buccal fat pad and buccal advancement flap was used.

**Conclusion:** Double layered closure is efficient in management of OAC. No dehiscence of flap was seen in study group. Comparatively 3 dehiscence was observed in control group, especially with large size defect. The postoperative sequel in both groups was similar.

**Keywords:** *oroantral fistula, combination flap, maxillary sinus, nasal regurgitation*

## Introduction

Oroantral Communication (OAC) is an unnatural communication between the oral cavity and maxillary sinus resulting from composite tissue loss involving the oral mucosa, alveolar bone and the sinus lining. It may occur subsequent to extraction of maxillary posterior teeth in close proximity to the sinus floor, during removal of cyst/ tumour in posterior maxilla or due to trauma or infection. Options available for management of OAC are variable and primarily depend on size of the defect. OAC which are 5 mm or smaller in diameter are most

likely to close spontaneously without the need of any surgical intervention.<sup>[1]</sup> Larger communications may often persist, and require surgical closure of the defect. Various techniques have been suggested in literature for closure of OAC, which range from simple primary closure, to use of buccal advancement flap, palatal rotation flap, split thickness skin graft, allogenic graft, regional flap, distant flaps, bone grafts, or buccal fat pad.<sup>[2]</sup> The surgical option used depends on type and size of the defect and surgeon's choice.

The conventional methods for management of OAC attain closure using a single layer of tissue, which can be mucosa (palatal rotation flap, buccal advancement flap), muscle (tongue flap, temporalis flap), bone graft (autogenous or alloplast) or adipose tissue (buccal fat pad). The present study intended to evaluate the efficacy of double layer closure using combination of buccal fat pad & buccal advancement flap in management of OAC and compare it with the conventional single layer closure using buccal fat pad.

### Materials and Method

The study was initiated after due approval of ethical committee and patients were enrolled after acquiring written informed consent. The study design used was prospective double blind randomized clinical trial. Patients with clinically evident OAC, secondary to varying aetiology were included in the study. The exclusion criteria included history of recurrent sinusitis, previous history of sinus surgery, immunocompromised patients, uncontrolled diabetes mellitus, history of radiation therapy, OAC subsequent to resection of malignancy and patients on long term steroid therapy. Patients were blindly allocated to group A (two layered closure with combination of buccal fat pad and buccal mucosa) or group B (single layer closure using buccal fat pad) using random allocation software (WINPEPI software version 11.65).

#### Surgical Procedure:

Patients in both groups were prescribed nasal decongestant (xylometazoline nasal spray), chlorhexidine oral rinse and antibiotic (amoxicillin 500 mg + clavulanic acid 125 mg BD), two days prior to the procedure, which was continued till 5th postoperative day. Choice of anaesthesia varied from local to general depending on case. The operator and the 1st assistant were kept same for all the cases. The size of the opening was measured in millimetres using graduated periodontal probe. Intra-operatively the lining of the OAC was freshened and the fistula tract was excised in case of long-standing communication. In group A, full thickness buccal mucoperiosteal flap was reflected, keeping the flap at least 0.5 cm anterior to the anterior margin of the defect. Periosteal scoring was done to mobilize the buccal flap for advancement over to the palatal side. Harvesting the buccal fat pad was done using blunt dissection, till

adequate bulk of fat was mobilized at the surgical site (figure 1d). The harvested fat was sutured to the palatal mucosa using 3-0 polyglactin (vicryl, Ethicon, violet braided) suture. Additionally, when required holes were drilled at bone over buttress area to stabilize the buccal fat pad anteriorly (figure 1e). The buccal mucosal flap was then advanced and sutured over the palatal mucosa using 3-0 polyglactin suture to attain a double layered primary closure (figure 1f). Patients in group B received a single layer closure using buccal fat pad. Duration of the procedure was measured from the time of incision to placement of the last suture using digital stop watch.

Immediate postoperative care was kept same for both groups. Patients were advised to eat soft diet, avoid vigorous oral rinses and blowing of nose. Analgesic (diclofenac sodium 75 mg BD) was prescribed for 7 days to patients of both groups. The parameters evaluated included the primary outcome (successful closure of OAC) and secondary outcomes (postoperative pain, swelling and mouth opening). The parameters were measured by different investigator and the operators were blinded from the same. The success of the surgery was judged based on complete closure of the oroantral communication with lack of any nasal regurgitation at one week and 1 month after the surgery. Pain was evaluated on 1st and 7th postoperative days using visual analogue scale (VAS). Patients were verbally asked to rate intensity of pain on scale of 0 to 10, with 0 being no pain and 10 being unbearable pain. Swelling was assessed preoperatively and on 1st and 7th postoperative days using flexible measuring tape. The horizontal dimension of swelling was measured from lower attachment of ear lobe to commissure of the mouth, while the vertical dimension of swelling was measured from angle of mandible to the outer cantus of the eye. The facial swelling was calculated by multiplying the horizontal and vertical dimensions of swelling. Percentage of change in facial swelling was calculated using formula;  $[(\text{postoperative value} - \text{preoperative value}) \div \text{preoperative value}] \times 100$ . Mouth opening was measured in millimetres as interincisal distance between central incisor teeth or between crest of alveolar ridge in edentulous patient on 7th postoperative day and at one month. The data collected was tabulated and analysed statistically.

## Results

Total of 27 patients, both males (n=16) and females (n=11) with clinical diagnosis of OAC and willing to participate in the study and follow-up were enrolled for the study. Patients were randomly allocated to group A (n=13) and group B (n=14). All the patients completed follow-up of 1 month and there was no dropout. The size of the defect varied from 11 to 40 mm with mean diameter of 28.23 mm in study group (A) as compared to 24.57 mm in the control group (B). The surgical procedure took more time in group A, with mean time of 42.23 minutes, as compared to 26.21 minutes in group B.

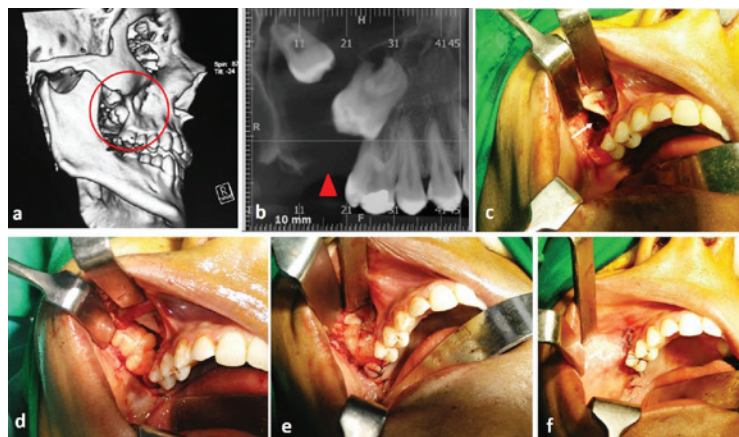
Postoperative pain was measured using VAS. The pain scores on 1st and 7th postoperative day were lower in group B (mean pain on 1st day was 1.71; with range of 1-3, while mean pain on 7th day was 0.21; with range of 0-1) as compared with group A (mean pain on 1st day was 1.768; with range of 0-4, while mean pain on 7th day was 0.538; with range of 0-2). Statistical analysis showed no significant difference between postoperative pain among the two groups.

Mann-Whitney U statistical test was used to assess the Percent change in facial swelling with significance level at 0.05. The mean percentage of change in facial swelling on 1st postoperative day in group A was 25.97%, as compared to 13.39% in group B. With the U value of 16 and z-score -3.6152, the difference was statistically significant (p-value 0.0003). There was considerable

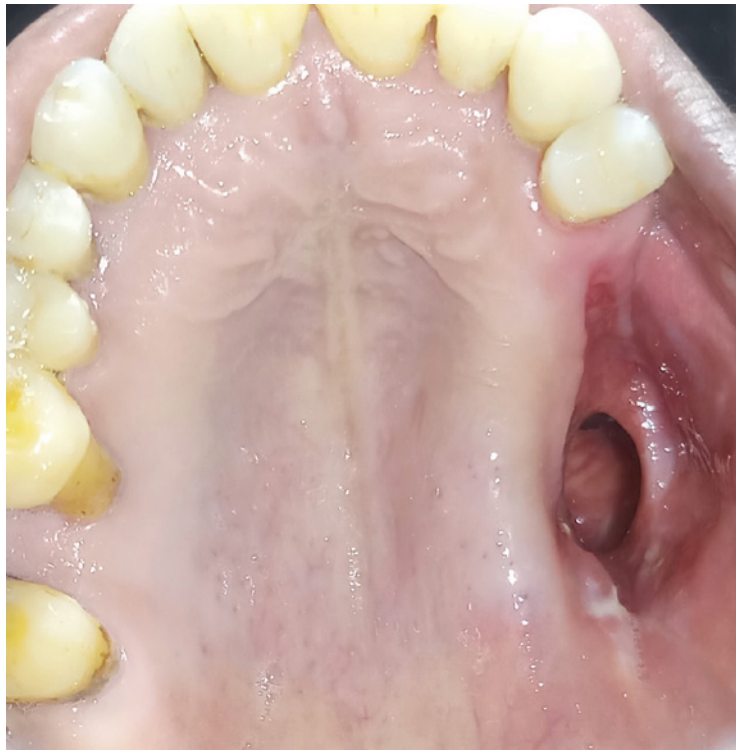reduction in percentage of facial swelling in both the groups on 7th postoperative day with mean of 05.44% and 02.64% in group A and B respectively. However, the difference of facial swelling between the two groups was statistically significant (p-value 0.03078).

The mouth opening was measured as interincisal distance preoperatively and on 7th postoperative day and 1 month. The interincisal distance on 7th postoperative day was 27.84 mm and 38.42 mm in group A and B respectively. T-Test was used for assessment of the two-independent means, with significance level of 0.05. The t-value at 7th day was -7.16975. The p-value was < .00001, which was statistically significant. The difference was close to preoperative baseline in both groups at one-month follow-up. The mean interincisal opening at 1 month was 39.61 mm and 40.85 mm respectively. The t-value was -0.776 and the p-value was 0.222, which was not significant statistically.

Evaluation of the primary outcome (success of surgery) included complete closure of the oroantral communication with lack of any nasal regurgitation. At 1-month follow-up no opening was seen in study group (group A). However, three patients (21.42%) in group B had dehiscence with oroantral communication. The patient who showed dehiscence had mean defect size of OAC of 35.33 mm, which was higher than the mean value of 24.57 mm for the entire group. Ecchymosis over buccal vestibule was seen in 3 patients of group A and 5 patients of group B. No other complications were seen in either group.



**Figure 1:** Intraoperative steps in closure of OAC using combination of buccal fat pad and buccal mucosal flap; preoperative imaging showing cystic lesion in posterior maxilla with involvement of maxillary sinus (a, b), surgical defect resulting in OAC after cyst enucleation (c), mobilization of buccal fat pad encapsulated within its lining at the surgical site (d), closure of the defect with fat pad, note anchorage of the fat with sutures through the hole drilled over maxillary buttress (e), buccal mucosa advanced and sutured to attain double layer closure.



**Figure 2: Dehiscence after surgical closure of large OAC using buccal fat pad.**

## Discussion

The present study intended to evaluate the efficacy of double layered closure (mucosa and fat) of composite defect of OAC. Traditionally both buccal fat pad and buccal advancement flap have been used independently for closure of OAC with varying success rate. Anatomically buccal fat pad is consolidated fat mass enclosed in thin capsule. It is present in the masticatory spaces of oro-maxillofacial region and contributes to the facial contour. This anatomic entity was first mentioned by Heister in 1732 and later described in detail by Bichat in 1802.<sup>[3]</sup> Egyedi first reported the use of buccal fat for repair of oral defects in 1977.<sup>[4]</sup> The fat mass receives its blood supply from vestibular branches of maxillary artery, transverse facial branches of superficial temporal artery and branches of facial artery. The rich blood supply and availability of the fat close to the defect of OAC explains its utility in management of OAC.

As advocated by Egyedi, conventionally buccal fat pad was lined with a skin graft, to aid in complete epithelization of the flap.<sup>[5]</sup> However, it is well documented that fat graft when used alone, adequately epithelizes on its own by 3<sup>rd</sup> to 4<sup>th</sup> week of inset.<sup>[6]</sup> There

is limited evidence in literature regarding use of double layered closure using combination of flap for closure of OAC.<sup>[7]</sup> Advantage of combining buccal fat pad with buccal mucosa appear to have an advantage in case of closure of large size defect, where the buccal fat pad tends to get unduly stretched or perforated. In all the cases of OAC treated with combination flap showed complete coverage with no dehiscence. Whereas use of single flap in control group, showed dehiscence in 21.42% cases. Dehiscence was seen in 3 cases with mean defect size of 35.33 mm, which was higher than the mean value of 24.57 mm for the entire group.

Candamourty R et.al. suggested that defects larger than 50 mm should be managed with combination of buccal fat pad with buccal advancement flap rather than fat pad alone.<sup>[8]</sup> Another indication for use of combination flap is lack of adequate volume of the fat graft available for harvest. The BFP has volume of 10 mL and weighs approximately 9.3 grams. When adequately dissected and mobilized it can provide 70×40×30 mm of pedicled graft.<sup>[9,10]</sup> However, the graft volume is greater in infants and children and reduces with age. Its size also varies among individuals. Volume of buccal fat pad may be inadequate in some cases, especially for large size defect

closure indicating the need of a combination flap.

Harvesting and inset of buccal fat pad is relatively simple. However, care should be taken to gently harvest the flap with blunt dissection without breakage of its thin capsule. The flap should be suture without tension. Anchoring of the fat tissue to the malar buttress after drilling holes through it was used to further stabilize the flap in the presented cases when indicated (figure 1e). This possibly adapts the flap better over the defect and when combined with mucosal layer provides composite closure of the OAC. Although relatively safe, minor complications have been associated with harvesting buccal fat pad which includes; haematoma, flap necrosis, scarring, infection and facial nerve damage.<sup>[11]</sup> Evaluation of post-operative sequel showed no statistically significant difference in pain and mouth opening between the two groups at 7<sup>th</sup> and 30<sup>th</sup> postoperative days respectively. However, swelling was relatively more when combination of buccal fat pad and buccal advancement flap was used, understandably because of greater tissue dissection and handling. Flap dehiscence was seen in 3 patients with single layer closure, whereas self-limiting ecchymosis in buccal vestibule was observed in total of 8 patients. No case of facial damage or infection was seen. Harvesting the flap in patients with previous radiotherapy, midface and malar hypoplasia and thin cheeks are relatively contraindicated. In the present cases contraindications of the procedure were; uncontrolled diabetes mellitus, history of radiation therapy, ablative defect after resection of malignancy and patients on long term steroid therapy. Double/composition flap took more time for completion of the procedure (group A-mean time of 42.23 minutes, group B-mean time 26.21 minutes). The greater time taken was due to need of harvesting of two flaps in group A as compared to one in group B.

### Conclusion

Combination of buccal fat pad and buccal advancement flap provides double layered closure of the composite defect of OAC. The technique is efficient in management of OAC and can be especially used in case of larger defect size. The postoperative sequel of using the combination flap is similar compared to single layer closure with buccal fat pad.

**Ethical Clearance-** Taken from Institution Ethical

committee of Krishna Institute of Medical Sciences Deemed to be University, Karad

**Source of Funding-** None

**Conflict of Interest:** None

### References

1. Lazow SK. Surgical management of the oroantral fistula: Flap procedures. *Oper Tech Otolaryngol Head Neck Surg.* 1999;10:148-52.
2. Visscher SH, van Minnen B, Bos RR. Closure of oroantral communications: A review of literature. *J Oral Maxillofac Surg.* 2010;68:1384-91.
3. Stuzin JM, Wagstrom L, Kawamoto HK, Baker TJ, Wolfe A. The anatomy and clinical applications of the buccal fat pad. *Plast Reconstr Surg.* 1990;85:29-37
4. Samman N, Cheung LK, Tideman H. The buccal fat pad in oral reconstruction. *Int J Oral Maxillofac Surg.* 1993;22:2-6.
5. Egyedi P. Utilization of the buccal fat pad for closure of oro-antral and/or oro-nasal communications. *J Maxillofac Surg.* 1977;5:241-4.
6. Singh J, Prasad K, Lalitha RM, Ranganath K. Buccal pad of fat and its applications in oral and maxillofacial surgery: A review of published literature (February) 2004 to (July) 2009. *Oral Surg Oral Med Oral Pathol Oral Radiol Endod* 2010;110:698-705.
7. Batra H, Jindal G, Kaur S. Evaluation of different treatment modalities for closure of oro-antral communications and formulation of a rational approach. *J Maxillofac Oral Surg* 2010;9:13-8.
8. Candamourty R, Jain MK, Sankar K, Ramesh Babu MR. Double-layered closure of oroantral fistula using buccal fat pad and buccal advancement flap. *J Nat Sc Biol Med* 2012;3:203-5.
9. Saha J, Pathak H, Poddar RN Use of buccal fat pad to repair intraoral defects. *J Indian Dent Assoc.* 2011;1:1-5
10. Fujimura N, Nagura H, Enomoto S. Grafting of the buccal fat pad into palatal defects. *J Craniomaxillofac Surg.* 1990;18:219-22.
11. Scott P, Fabbroni G, Mitchell DA. The buccal fat pad in the closure of oro-antral communications: an illustrated guide. *Dent Update* 2004;3:363-366.