

Ultrasound Value in Diagnosis of Acute Appendicitis at Al-diwanayah Teaching Hospital-Iraq

Shaimaa A. Kadhum Al-Zubaidi

M.D. Diagnostic Radiology/Lecturer at College of Medicine-University of Al-Qadisiyah, Iraq, Diwanayah, Iraq

Abstract

Background: Ultrasound has been widely available and usable imaging technique help in assessment and diagnosis of various diseases. The use of ultrasound as diagnostic tool for diagnosis of appendicitis has been established, but the real value of use of ultrasound not clearly observed, the aim of our study to clarify the negativity of the predictive value of ultrasound study for acute appendicitis (NVP).

Method: Ultrasound study of the abdomen with focusing on right iliac fossa done for 100 patient clinically suspected to have acute appendicitis and a scale of one to three given for sonographic results range from negative (score 1) to confirmed appendicitis (score 3), the result compared with the CT – scan finding and specimen pathology after surgical intervention.

Result: Seventy four (74) patient were negative by ultrasound, while twenty six (26) patient has score of 3 ultrasonic features of acute appendicitis, CT scan examination with contrast adding another ten (10) patient proved to have appendicitis (i.e changing from negative to positive appendicitis by CT findings) and fifteen (15) patient with other diagnosis or discharged, so total positive cases where thirty six (36) patients whom underwent surgical intervention, from those were thirty (30) patient confirmed appendicitis by pathological result (83%), So the negative predictive value for the ultrasound diagnosis of appendicitis (NVP = 95.1%).

Conclusions: Ultrasound had an overall lower sensitivity in diagnosing appendicitis in our study, but with high specificity, however, with various studies when the appendix was not clearly identified, CT-scan assessment should be considered .

Keyword: *Appendicitis, ultrasound, diagnosis of appendicitis, sonographic assessment.*

Introduction

A painful abdomen is common, acute appendicitis is the commonest suspected disease and must be differentiated from other pathology^(1,2,3). Although, the main points for diagnosis that patient commonly present with pain around the umbilicus which radiated

to right lower abdomen, with nausea, vomiting, fever, leukocytosis with neutrophilia.⁽⁴⁾ Imaging studies are much helpful in diagnosis when the clinical picture are not too clear, were studies support the use of ultrasound with/without CT- scan for confirmation of acute appendicitis.^(1,2,3,4,5) Were the sensitivity of ultrasound ranging from (67% - 88%) and specificity about (78% -100%), while the sensitivity of CT-scan about (76% -96%) and specificity about (75% - 97%).^(7,8) The study aiming to assess the negativity of the predictive value of ultrasound study and if can be used for screening of acute appendicitis ..^(10,12)

Corresponding Author:

Shaimaa A. Kadhum Al-Zubaidi

M.D. Diagnostic Radiology/Lecturer at College of Medicine-University of Al-Qadisiyah, Iraq, Diwanayah, Iraq

e-mail: shaimaa.alzubaidi@qu.edu.iq

Materials and Method

Study begin in Al-diwanayah teaching hospital in the period between October 2018 and October 2019, were

100 patient complaining of clinical features of acute appendicitis seeking the surgical and radiological in-hospital clinic has been chosen randomly and included in our study, each ultrasound study done by specialist radiologist, were superficial and convex probe used. The examination focusing on region of right iliac fossa by using graded compression technique and viewed in longitudinal and transverse images, then a score of three points we depend upon to assess the clarify the possible available radiological findings, by which : Score 1 (normal appendix, regarded as negative result) Score 2 (appendix cant seen or minimal secondary signs of appendicitis like peri-cecal free fluid, or increment in the peri-cecal echogenicity with thickening of the fat of the mesentery and presence of faecolith or the size

range from 5-6 mm, regarded as equivocal and need further assessment). Score 3 (clear sonographic features of appendicitis like enlarged non-compressible appendix with diameter of 7 mm or more, regarded as positive result), as shown in figure (1). CT-scan with 2 ml/kg iodine based contrast media with 5mm axial imaging protocol for abdomen used, in some cases with abdominal pain more than one day, an oral contrast has been given also. Fig 2 Criteria for positive acute appendicitis in CT-scan are an appendix diameter of the appendix exceed six millimeter, stranding of the surrounding fat stranding, wall enhancement of the tissue of the wall, and abscess around the appendix.

We correlate the radiological finding with surgical and pathological result with definitive diagnosis.

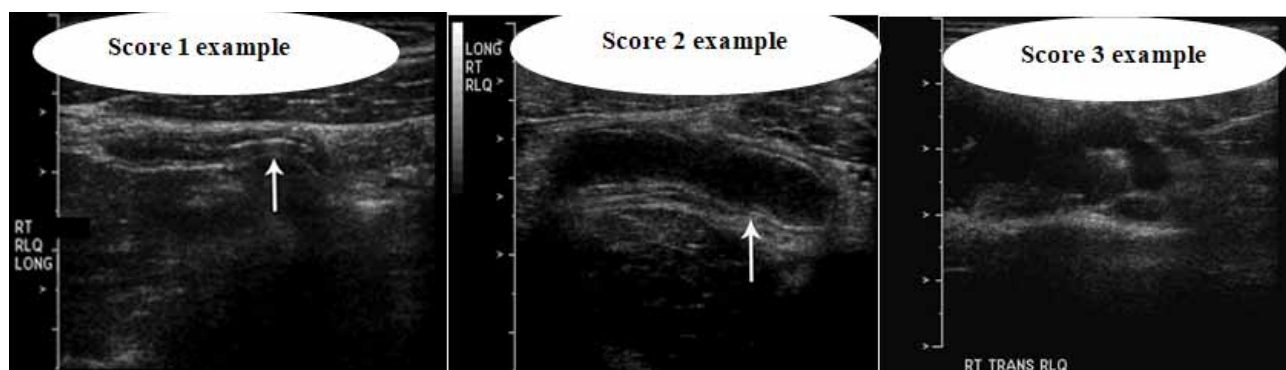


Figure (1) Ultrasound score 1-3.

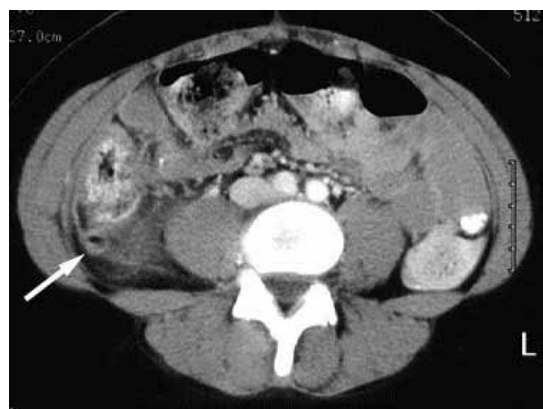


Figure (2) appendicitis by CT scan.

Statistics: The accuracy of diagnosis of ultrasound study was assessed by using the positive and negative predictive value, sensitivity and specificity and their respective, negative and positive likelihood ratios. the values regarded as estimated values and 95% confidence intervals.

Results

From the 100 appendicitis diseased complainers selected for study and undergo the ultrasonic examination, 74 patient had negative ultrasound scan, and 26 have positive ultrasound scan.

Those 100 patients then undergo CT scan with contrast for the abdomen/pelvis and changing the result of 10 patient from negative to positive i.e. with CT-scan the positive became 36 patient, and 64 patients negative or had another diagnosis.

Those 36 patient underwent surgical intervention and pathological assessment, from whom 30 patient were proved to have appendicitis and 6 patient were negative by pathology, so the sensitivity of ultrasound was (75 %), specificity was (92 %), positive predictive value (85 %), CI (46.2%–74.4%) and the negative predictive value (NPV) about (95.1%).

Discussion

Acute appendicitis suspicion is regarded as one of the mysterious cases encountered in clinical medicine, diagnosis is mainly based on clinical practice, but sometimes the case can be missed.^(13,17)

Radiological imaging has a vital role in the updated assessment of appendicitis, although the best radiological assessment remains unclear.⁽¹⁹⁾

The ideal imaging protocol should obey the following criteria which are availability, non-expensive, reproducibility, safety, fast test, and accurate one.⁽¹⁸⁾

X-ray images findings are not precise, but the presence of appendicolith is diagnostic of appendicitis, however its present in less than (5%) of acute appendicitis.^(19,20)

Studies that use of sonography and CT-scan in the assessment of acute appendicitis focusing on the visualization rate of the appendix with clarifying the specificity and sensitivity of the study.^(1,5,14)

Ultrasound examination is helpful in assessment of female, to avoid radiation to feminity organs to exclude ovarian and uterine diseases that might resemble clinical picture of acute appendicitis.⁽²¹⁾

In the study the diseases of the ovary and uterus with pain were found in 14 patients, or another diagnosis found⁽²²⁾.

The most criterion for the diagnosis of appendicitis by ultrasound are the identification of a non-compressible blind-ending tubular structure in the region of the right iliac fossa with an outer diameter of more than six millimeter⁽²³⁾.

Older researches suggested that to exclude acute appendicitis, a normal appendiceal structure should be recognize⁽²⁴⁾.

The sonographic visualization rate varies greatly between hospitals, from about 98% to 22%.⁽¹⁸⁾ In our study, negative result mean non visualization of appendix and no other signs of appendicitis, depending on these principles, the NPV was about (95.15 %), is similar to results in older studies.^(10,24)

The indication of use of CT- scan after ultrasound study included non-visualization, non-conclusive visualization of secondary signs of appendiceal

inflammation, or negative but still with associated suspicion for acute appendicitis.^(10,12,24)

The positive predictive value in the study was relatively lower than others^(10,11,24) which could be contributed the low pretest probability of the disease in our population⁽²²⁾.

The retrospective design added a limitation to our study, as the examinations are highly depend on the operator. However, the study was supported by the using a rigorous exclusion protocol for acute appendicitis in our hospital.^(19,20,21)

Our conclusion, ultrasound was found to have a high negative predictive value (95.15 %) for the exclusion of appendicitis even when the appendix can-not be seen. The role of ultrasound use in young female is supportive especially to protect their reproductive organs from radiation of other modalities, which could be done when clinical status deteriorated or still highly suggestive of acute appendicitis.⁽¹⁴⁾

Ethical Clearance: The Research Ethical Committee at scientific research by ethical approval of both MOH and MOHSER in Iraq.

Conflict of Interest: None

Funding: Self-funding

References

1. Kaiser S, Frenckner B, Jorulf HK. Suspected appendicitis in children: US and CT—a prospective randomized study. *Radiology* 2002; 223:633–638.
2. Sivit CJ, Siegel MJ, Applegate KE, Newman KD. When appendicitis is suspected in children. *Radiographics* 2001;21:247–262, questionnaire 288–294.
3. van Breda Vriesman AC, Puylaert JB. Mimics of appendicitis: alternative nonsurgical diagnoses with sonography and CT. *AJR Am J Roentgenol* 2006; 186:1103–1112.
4. Lee SL, Ho HS. Acute appendicitis: is there a difference between children and adults? *Am Surg* 2006; 72:409–413.
5. Johansson EP, Rydh A, Riklund KA. Ultrasound, computed tomography, and laboratory findings in the diagnosis of appendicitis. *Acta Radiol* 2007; 48:267–273.
6. Gracey D, McClure MJ. The impact of ultrasound

- in suspected acute appendicitis. *Clin Radiol* 2007; 62:573–578.
7. Gamanagatti S, Vashisht S, Kapoor A, Chumber S, Bal S. Comparison of graded compression ultrasonography and unenhanced spiral computed tomography in the diagnosis of acute appendicitis. *Singapore Med J* 2007; 48:80–87.
 8. Baldisserotto M, Peletti AB. Is colour Doppler sonography a good method to differentiate normal and abnormal appendices in children? *Clin Radiol* 2007; 62:365–369.
 9. Doria AS, Moineddin R, Kellenberger CJ, et al. US or CT for diagnosis of appendicitis in children and adults? A meta-analysis. *Radiology* 2006; 241:83–94.
 10. Assefa G, Meseret S, Nigussie Y. The role of ultrasound in diagnosing acute appendicitis. *Ethiop Med J* 2006; 44: 67–74.
 11. Kaiser S, Jorulf H, Söderman E, Frenckner B. Impact of radiologic imaging on the surgical decision-making process in suspected appendicitis in children. *Acad Radiol* 2004; 11:971–979.
 12. Incesu L, Yazicioglu AK, Selcuk MB, Ozen N. Contrast-enhanced power Doppler US in the diagnosis of acute appendicitis. *Eur J Radiol* 2004; 50:201–209.
 13. Poortman P, Lohle PN, Schoemaker CM, et al. Comparison of CT and sonography in the diagnosis of acute appendicitis: a blinded prospective study. *AJR Am J Roentgenol* 2003; 181:1355–1359.
 14. Lowe LH, Penney MW, Stein SM, et al. Unenhanced limited CT of the abdomen in the diagnosis of appendicitis in children: comparison with sonography. *AJR Am J Roentgenol* 2001; 176:31–35.
 15. VassarStats. Utilities/convert to standard scores. VassarStats website. <http://faculty.vassar.edu/lowry/VassarStats.html>. Accessed November 2, 2009.
 16. Newcombe RG. Two-sided confidence intervals for the single proportion: comparison of seven methods. *Stat Med* 1988; 17:857–872.
 17. Rodriguez DP, Vargas S, Callahan MJ, Zurakowski D, Taylor GA. Appendicitis in young children: imaging experience and clinical outcomes. *AJR Am J Roentgenol* 2006; 186: 1158–1164.
 18. Taylor GA. Suspected appendicitis in children: in search of the single best diagnostic test. *Radiology* 2004; 231:293–295.
 19. Rao PM, Rhea JT, Rao JA, Conn AK. Plain abdominal radiography in clinically suspected appendicitis: diagnostic yield, resource use, and comparison with CT. *Am J Emerg Med* 1999; 17:325–328.
 20. Old JL, Dusing RW, Yap W, Dirks J. Imaging for suspected appendicitis. *Am Fam Physician* 2005; 71:71–78.
 21. Siegel MJ, Carel C, Surratt S. Ultrasound of acute abdominal pain in children. *JAMA* 1991; 266:1987–1989.
 22. Puylaert JB. Acute appendicitis: US evaluation using graded compression. *Radiology* 1986; 158:355–360.
 23. Wiersma F, Sramek A, Holscher HC. US features of the normal appendix and surrounding area in children. *Radiology* 2005; 235:1018–1022.
 24. Chang YJ, Kong MS, Hsia SH, et al. Usefulness of ultrasonography in acute appendicitis in early childhood. *J Pediatr Gastroenterol Nutr* 2007; 44:592–595.