

Ultrasonographic Evaluation of Thyroid Masses with Pathologic Correlation

Basumatari Bharati¹, Hazarika Devid², Mahanta Putul³, Borah Pollov⁴

¹Assistant Professor, Department of Radiology, Fakhruddin Ali Ahmed Medical College and Hospital, Barpeta-Jania Rd, Joti Gaon, Assam 781301, ²Assistant Professor of Surgery, Assam Medical College, Dibrugarh, Assam, India, ³Professor of Forensic Medicine, Assam, India, ⁴Associate Professor of Anaesthesia, Jorhat Medical College, Jorhat, Assam, India

Abstract

Introduction: Thyroid gland is easily accessible to both clinical and radiological examinations. The thyroid masses must be diagnosed and managed as early as possible to rule out malignancy. Thyroid masses are typically found on physical examination or incidentally when other imaging studies are performed.

Objectives: Evaluation of the clinical profile of thyroid masses with ultrasonography (UGC) of the patient having thyroid lesions with pathologic correlation.

Materials and Method: This prospective study was a cross-sectional descriptive one, which was conducted over the 50 subjects with thyroid masses detected on USG, were further evaluated with Fine-needle Aspiration Cytology (FNAC) and Histopathological Examination (HPE). The USG features such as internal composition, echotexture, shape, margins, presence or absence of peripheral halo, calcification and internal vascularity were correlated with the final diagnosis. The collected data were subjected to a statistical analysis which was performed using a Statistical Package for the Social Sciences (SPSS) software version 20.0. Descriptive statistical method were computed, and the statistical significance was tested by chi-square test and student's t-test. A p-value of less than 0.05 was considered statistically significant. Ethical clearance was taken from ethics committee (H).

Results: In USG diagnosis, goitre is the most common benign lesion in 63% followed by benign cyst 16%. Follicular carcinoma, medullary carcinoma and undifferentiated carcinoma 1 case of each variety was also detected at USG. Cytological examination of 50 cases, 44 (88%) cases revealed benign nature of thyroid swelling and 6 (12%) cases as malignant. The malignant thyroid cases diagnosed clinically and cytologically.

Conclusion: USG and FNAC with HPE are the primary diagnostic modalities a surgeon utilizes to determine the extent of thyroid surgery.

Keywords: *Thyroid nodule; FNAC; Thyroid cancer; Molecular markers.*

Introduction

The thyroid mass is a common thing. While autopsy data indicate a 50% prevalence of thyroid nodules larger

than one centimetre in patients without clinical evidence of thyroid disease, the prevalence of palpable nodules is only 4 to 7%.^{1,2}

USG is far more sensitive than palpation, as it detects nodules of any size in up to 67% of the general population.³ Thyroid nodules warrant removal when they are large enough to be symptomatic, or if there is a concern for malignancy. The majority of nodules are asymptomatic, and with only 5 to 10% of nodules being malignant, the decision to operate is made on therapeutic or diagnostic grounds.^{4,5}

Corresponding Author:

Borah Pollov

Associate Professor of Anaesthesia, Jorhat Medical College, Jorhat, Assam, India
e-mail: drpollov@gmail.com
Mobile: +919435030948

Ultrasound imaging studies and cytology from FNAC are the main tools used by the clinician to decide whether surgical excision of a thyroid nodule is warranted. Molecular genetic biomarker analyses are now being used to increase the accuracy of FNAC, and appear to substantially alter the clinical decision-making process as they become more widely available and more thoroughly evaluated.⁶

Alongside USG, FNAC found to be rapid, simple, safe, and cost-effective diagnostic modality in the investigation of thyroid disease with high sensitivity, specificity, and accuracy. It can be used as an excellent first-line method for investigating the nature of lesion.⁷

Therefore, in this paper, the USG evaluation of the thyroid masses with pathologic correlation was done.

Materials and Method

This study was a cross-sectional descriptive one, which was conducted in the Department of Radiology with the help of the department of pathology at Gauhati Medical College Hospital. A total of 50 subjects were subjected to this research. All the patients were selected from outpatient departments and indoor wards of various departments (mostly from ENT & Surgery department). A thorough clinical examination was done in all the cases and the data were recorded accordingly in pre-designed pre-tested proforma.

Initially, a thorough clinical examination was done in all the cases and followed by necessary routine and special investigations were done as when it is necessary. In 62 cases FNAC was done and postoperative histopathology was done. In 12 cases FNAC report was inclusive and so they are excluded from the study. In 50 cases both cytological and histopathological examination was done and the results were correlated and analyzed independently.

For USG, patients were examined in the supine position on the USG table with the neck mildly hyperextended so that the examination can be done thoroughly. When the possible patient is examined with quiet breathing and swallowing suspended. The examination is completed with Colour Doppler study.

After taking the proper history, clinical examination and laboratory investigations, the patient is prepared for USG with a fully extended neck. Hitachi and Seimens Colour Doppler, Linear probe 13MHz is used for USG.

Apart from routine blood investigation, X-Ray- A.P. & lateral view of the neck, P.A. View of the chest was done. The clinical diagnosis was done with Cytological examination (FNAC).

Finally, the data were subjected to a statistical analysis which was performed using a Statistical Package for the Social Sciences (SPSS) software version 20.0. Descriptive statistical method were computed, and the statistical significance was tested by chi-square test and student's t-test. A p-value of less than 0.05 was considered statistically significant. Ethical clearance was taken from ethics committee (H).

Result

The present study is an analysis of USG of the thyroid swelling with pathologic correlation. Initially, 62 patients of thyroid swelling were taken for this study. Out of that only 50 cases were selected because the other 12 cases don't give the adequate amount of aspirate.

Benign lesion diagnosed by USG: In USG diagnosis, goitre is the most common benign lesion in 63% followed by benign cyst 16% as shown in Figure 1.

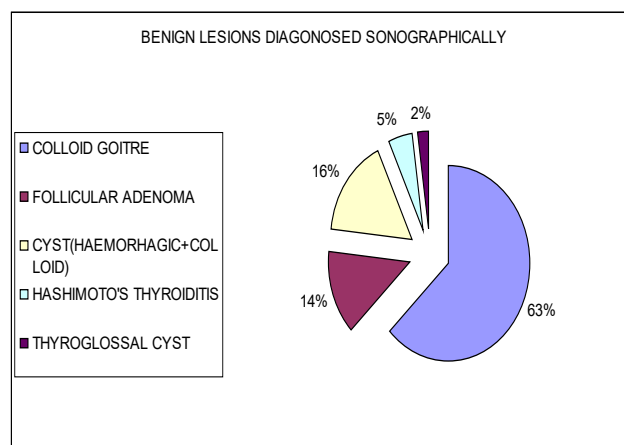


Figure 1: Benign lesion diagnosed ultrasonographically

Malignant tumour diagnosed by USG: Follicular carcinoma, medullary carcinoma and undifferentiated carcinoma 1 case of each variety were detected at USG.

Distribution of thyroid lesion in order of frequency of ultrasonography report: The distribution of thyroid lesion in order of frequency of ultrasonography report is shown in **Figure 2**.

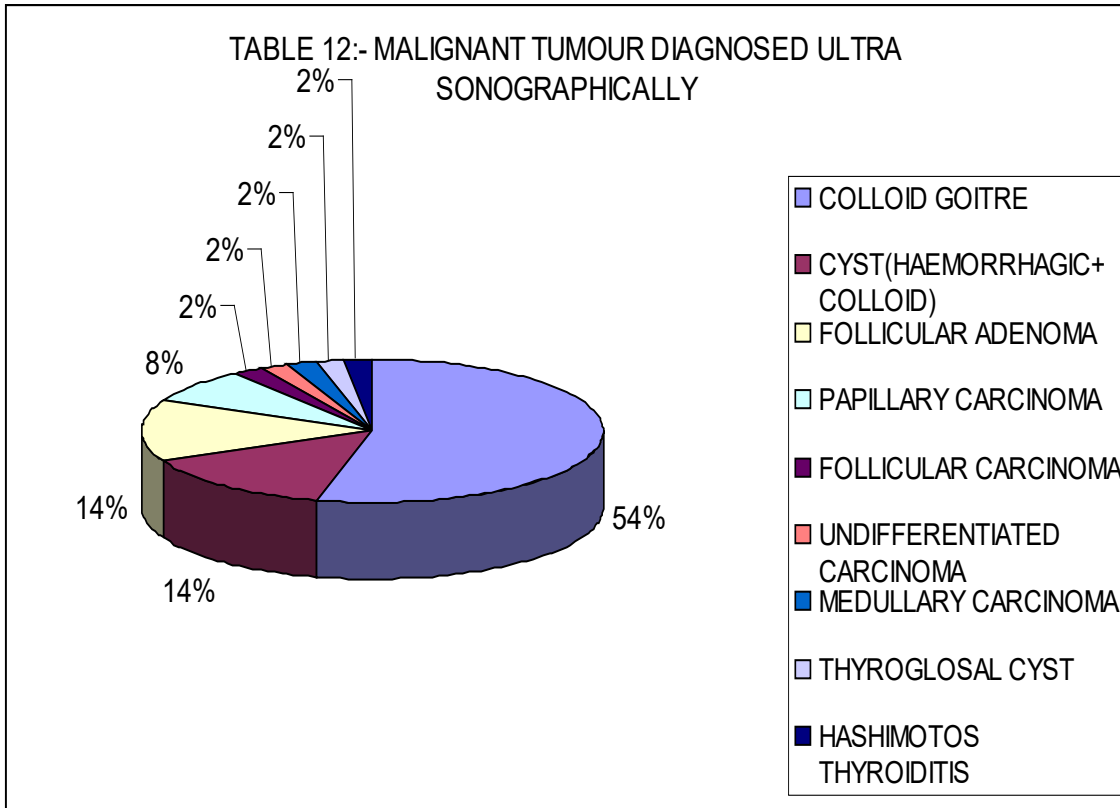


Figure 2 Distribution of thyroid lesion in order of frequency of ultrasonography report

Benign lesion diagnosed cytologically: Cytological examination of a total of 50 cases revealed benign nature of thyroid swelling in 44 cases (88%) and malignancy in 6 cases (12%). Among the malignant thyroid cases diagnosed clinically and cytologically, 3 cases were referred to B. Barooah Cancer Institute for further management.

Table 1 Various benign lesion diagnosed cytologically

Diagnosis	Number of patients	Percentage
Colloid Goiter	27	54
Follicular Adenoma	7	14
Subacute-Thyroiditis	1	2
Hyperplastic Nodule	1	2
Cyst	8	16
Total	44	88%

The cytologically diagnosed benign group contains 54% of colloid goitre, 16% of the benign cyst (hemorrhagic and colloid cyst) and follicular adenoma

of 14% of cases. Subacute-thyroiditis and hyperplastic thyroid nodule are 2% each as shown in **Table 1**.

Criteria for cytological diagnosis of the benign lesion was set as follows:

For Colloid goitre:

1. Abundant colloid.
2. Follicular –cell is scanty, microfollicular structure occasionally preserved.
3. Degenerated RBC.
4. Free phagocytes with foamy cytoplasm.

Follicular adenoma:

1. Colloid material is usually scanty.
2. A number of the follicular cell are high and arranged in monolayer. They usually preserved follicular structure.

Subacute-thyroiditis: They usually shows polymorphonuclear leukocyte, necrotic tissue and few follicular cells.

Type of thyroid lesion diagnosed cytologically:
 Out of 50 cases, 6 cases are found to be malignant on cytology. Out of the 33% is papillary carcinoma and follicular carcinoma each. And medullary carcinoma and anaplastic carcinoma are 17% each. Criteria for diagnosis malignant lesion cytologically:-

Follicular carcinoma:

1. Increase nuclear size.
2. Increase cellularity.
3. Decrease the amount of colloid.
4. Microfollicular structure preserved.

Papillary carcinoma:

1. Increase cellularity.
2. Scanty colloid.

3. A papillary cluster of the cell.
4. Variation of cell size.
5. PSAMMOMA bodies (laminated calcification).
6. Intranuclear cytoplasmic inclusion.

Anaplastic Carcinoma:

1. Cell with either single or multiple nuclei present.
2. Necrotic material, cell debris, inflammatory cells mainly granulocytes present.

Correlation between ultrasonography and cytodiagnosis of different thyroid swelling: Our study shows the fallacy in diagnosing malignant lesion. In benign lesion, its accuracy is quite high as shown in **Table 2**.

Table 2 Correlation between ultrasonography and cytodiagnosis of thyroid swelling

Type of lesion	Diagnosed at USG		Diagnosed at FNAC		% of diagnostic accuracy
	Number of cases	%	Number of cases	%	
Colloid goiter	27	54	27	54	100
Follicular adenoma	7	14	6	12	85.7
Cyst	8	16	8	16	100
Hurthle cell adenoma	0	0	1	2	0
Papillary carcinoma	2	4	4	8	50
Follicular carcinoma	2	4	1	2	50
Medullary carcinoma	1	2	1	2	100
Undifferentiated carcinoma	1	2	1	2	100
Hyperplastic thyroid nodule	1	2	0	0	0
Hashimoto's thyroiditis	1	2	1	2	100
	50		50		

Diagnostic accuracy of cytology: In 50 cases where the result of ultrasonography was confirmed by cytology, the diagnosis was accurate in 47 (94%) cases and inaccurate in 3 (6%) cases. Two cases of papillary carcinoma diagnosed as benign adenoma and one case of follicular adenoma were diagnosed as follicular carcinoma as shown in **Table 3**.

Table 3 Diagnostic accuracy of cytology

Types of lesion	Ultrasonography		Cytology			
	Number of cases	%	Accuracy		Inaccuracy	
			Number of cases	%	Number of cases	%
Benign	43	100	42	97.67	1	2.33
Malignant	7	100	5	71.43	2	28.57
Total	50		47			
Overall		100		94		6

Cytological pitfalls: Among the study of 50 cases false positive was found in one case of follicular adenoma as follicular carcinoma and two cases two papillary carcinomas as follicular adenoma. Our study shows the fallacy in diagnosing malignant lesion.

Discussion

Evaluation of thyroid pathology is one of the most common problems encountered in day today medical practice and the brunt of its diagnosis is falls on ENT and Head & Neck surgeon. Almost affecting the thyroid like degenerative diseases, hyperthyroidism, thyroiditis, a benign or malignant tumour can present as a circumscribed or diffuse swelling. Moreover, most of the patient are female so we have to take care of proper cosmetic. We should also try to preserve the normal function of thyroid for all cases in the rest of the life postoperatively.

Radioactive thyroid imaging focuses attenuation on non-functioning areas, but at least 80% of these are benign. Ultrasound has proved useful in delineating cystic lesion, through up to 10% of which may harbour malignant.⁸

The rate accuracy of the benign lesion was 97% and malignant was 69%. The overall accuracy rate was 92% excluding false-positive and false-negative result. The rate of accuracy documented in the present study is consistent with Marqusee E et al.⁹

Although the number of cases in our study was small the accuracy rate was quite high in comparison to the above studies. Out of 50 cases in 3 (6%) cases, USG was inaccurate, out of these three cases, one case was diagnosed as follicular adenoma as follicular carcinoma and two cases of papillary carcinoma diagnosed as follicular adenoma. Thus the false positive report was 2% and the false-positive was 4%. As reported by in a study⁸ false-positive report was 3.3% in our study, we take the small number of cases so false-negative result shows high value. Moreover, in most of the patients, we have taken the aspiration from one site which may not be the proper site of aspiration in cases of a malignant lesion. So if we had taken the aspiration from multiple sites than false-negative rate may be decreased. In our series of study, we have taken the aspiration just after clinical examination and palpation of swelling. With the help of the USG technique, we select the proper site for aspiration in our study one case of follicular adenoma is missed diagnosed as follicular carcinoma. Another two

cases of papillary carcinoma were diagnosed as follicular adenoma. It may be because in follicular adenoma also cellularity of the smear increases colloid become scanty and monomorphic mono layered follicular cell are present, which are also the characteristic of papillary carcinoma. Moreover in papillary carcinoma intranuclear cytoplasmic invagination and psammoma bodies is the characteristic finding. In these studies, our aspirated material may not be sufficient enough or maybe not from the proper site to demonstrate the specific cytology.

In the present series clinically we have found 58% of the solid nodule, 16% of cystic and rest of mixed consistency. J Martin Miller et al.¹⁰ he reported 82% solid 11% cystic 7% mixed consistency.

When the result of the USG was compared with cytology it was observed than out of 7 malignant cases were misdiagnosed as a benign lesion. Two cases of papillary carcinoma as follicular adenoma and one case of follicular adenoma as follicular carcinoma. In our study shows 100% accuracy in the diagnosis of the benign cystic lesion which includes benign colloid cyst and benign hemorrhagic cyst.

In our present study, the diagnosis of the benign lesion in colloid goitre was made from the simple pattern of colloid and follicular cells.

Conclusion

The majority of thyroid nodules are benign, but they warrant surgical excision when they are large enough to be symptomatic or if there is a concern for malignancy. Ultrasound is the primary study by which the thyroid gland is imaged. However, some masses with sonographically suspicious warrant cytologic analysis through fine-needle aspiration biopsy to determine the risk of malignancy. USG and FNAC are the primary diagnostic modalities a surgeon utilizes to determine the extent of thyroid surgery.

Ethical Clearance: Taken.

Source of Funding: None.

Conflict of Interest: None.

References

1. Mortensen JD, Woolner LB, Bennett WA. Gross and microscopic findings in clinically normal thyroid glands. *J Clin Endocrinol Metab* 1955; 15(10):1270–80.

2. Singer PA. Evaluation and management of the solitary thyroid nodule. *Otolaryngol Clin North Am* 1996;29(4):577–91.
3. Ezzat S, Sarti DA, Cain DR, Braunstein GD. Thyroid incidentalomas. Prevalence by palpation and ultrasonography. *Arch Intern Med* 1994;154(16):1838–40.
4. Papini E, Guglielmi R, Bianchini A, Crescenzi A, Taccogna S, Nardi F, et al. Risk of malignancy in nonpalpable thyroid nodules: predictive value of ultrasound and color-Doppler features. *J Clin Endocrinol Metab* 2002;87(5):1941–6.
5. Nam-Goong IS, Kim HY, Gong G, Lee HK, Hong SJ, Kim WB, et al. Ultrasonography-guided fine-needle aspiration of thyroid incidentaloma: correlation with pathological findings. *Clin Endocrinol (Oxf)* 2004;60(1):21–8.
6. Steven R Bomeli, Shane O LeBeau, Robert L Ferris. Evaluation of a thyroid nodule. *Otolaryngol Clin North Am* 2010 Apr;43(2):229–238. doi: 10.1016/j.otc.2010.01.002
7. Richa Bhartiya, Mahasweta Mallik, Nawanita Kumari, and Brijendra Narayan Prasad. Evaluation of thyroid lesions by fine-needle aspiration cytology based on Bethesda system for reporting thyroid cytopathology classification among the population of South Bihar. *Indian J Med Paediatr Oncol*. 2016 Oct-Dec; 37(4): 265–270. doi: 10.4103/0971-5851.195742
8. Martin P Sandler, James A Patton, Barry M McCook. Multimodality imaging of the thyroid gland. *Baillière's Clinical Endocrinology and Metabolism* 1989;3(1):89-119.
9. Marqusee E, Benson CB, Frates MC. The usefulness of ultrasonography in the management of nodular thyroid disease. *Ann Intern Med* 2000;133(9):696–700.
10. J Martin Miller, Joel I Hamburger, Sudha Kini. Diagnosis of Thyroid Nodules Use of Fine-Needle Aspiration and Needle Biopsy. *JAMA* 1979; 241(5):481-484. doi:10.1001/jama.1979.03290310021006