

Cassava Leaves Extract (*Manihot esculenta*) Prevents the Decrease of Albumin Serum Level in Mice with Gentamicin-Induced Hepatotoxicity

Rosita Dewi¹, Rena Normasari²

¹Lecturer, Histology Department, Faculty of Medicine, University of Jember, ²Lecturer, Pathology Anatomy Department, Faculty of Medicine, University of Jember, Jalan Kalimantan No. 37 Kampus Tegalboto, Jember, 6812, East Java, Indonesia

Abstract

Gentamicin is effectively used for the treatment of gram-negative bacterial infection but it has a hepatotoxic effect. Lipid peroxidation and suppression of endogenous antioxidants by gentamicin increases the production of reactive oxygen species which leading to necrosis of hepatocyte. Cassava leaves (*Manihot esculenta*) contain phenolic compounds, flavonoids, vitamin C, carotene, and iron which act as antioxidant and enzymatic antioxidant cofactor which can inhibit lipid peroxidation. This research aimed to determine the influence of cassava leaves extract to serum albumin level in mice with gentamicin-induced hepatotoxicity. Mice were divided into groups N, K (gentamicin 80 mg/kg b.w.); P1, P2, P3 (gentamicin 80 mg/kg b.w. and cassava leaves extract 150 mg/kg b.w., 300 mg/kg b.w., 450 mg/kg of b.w. for 14 days). Serum albumin level in group K was decreased compared to group N; group P1, P2, P3 were respectively gradually increased. One Way Anova analysis showed significant difference among groups ($p < 0.05$). Post Hoc Tukey test showed that serum albumin level in group P3 was significantly different from group K ($p < 0.05$). It can be concluded that cassava leaves extract prevent the decrease of serum albumin level in mice with gentamicin-induced hepatotoxicity.

Keywords: Cassava leaves, hepatotoxicity, gentamicin, albumin.

Introduction

Liver is the largest organ in the body that plays an important role in the metabolism and detoxification of various types of chemicals¹⁻⁴. Related to this function, liver cells are very susceptible to damage. The level of liver cell damage depends on the type, dose, and duration of exposure to chemicals⁵. Chemicals such as drugs can induce liver damage⁶. The pathogenesis of liver damage involves inhibition of the mitochondrial respiration chain which will increase the number of reactive oxygen

species (ROS) and decrease the amount of adenosine triphosphate (ATP). Generation of ROS and ATP depletion triggers intracellular damage, inflammation, and death of liver cells through the necrosis pathway⁶⁻⁸. Laboratory tests to support the diagnosis of liver damage include liver enzymes, namely increased alanine transaminase (ALT) and aspartate transaminase (AST), increased bilirubin, and decreased albumin; examinations of liver imaging include ultrasound, CT-scan, MRI; and liver biopsy^{6,9}. Albumin level can be used as a predictor of prognosis for liver damage¹⁰.

A six-year study in Denmark reported that six patients underwent liver transplants and nine patients died of liver damage with the etiology of antibiotic use¹⁰. A 16-year Cohort study in Italy stated that 23.4% of liver damage was caused by antibiotics⁹. In the United States (US), 50% of 1600-2000 cases of acute liver failure per year are caused by drugs and 30% of patients who

Corresponding Author:

Rosita Dewi

Histology Department, Faculty of Medicine, University of Jember

e-mail: rosita.fk@unej.ac.id

undergo liver transplantation die⁶. Another study in the US stated the incidence of acute drug-induced liver failure 0.59 per 1,000,000 population with antibiotics as the second highest etiology¹⁰.

Gentamicin which is used in the treatment of severe infections by gram-negative bacteria in the US is the cause of hepatotoxicity¹¹. The nephrotoxic and ototoxic effects of gentamicin have been extensively studied, while the hepatotoxic effects have not been extensively studied. Structural damage and similar declines in liver function were reported due to gentamicin 80 mg/kg b.w. for 7 days¹². Lipid peroxidation by gentamicin will cause cell membrane damage which will result in cell necrosis. The effect of gentamicin suppression on endogenous enzymatic and nonenzymatic antioxidants will increase the production of reactive oxygen species (ROS) which not only damage lipid membranes but also proteins and nucleic acids.^{2,3,11}.

Plants are widely used as a source of natural antioxidants that are safe and effective^{2,3}. One example of food plants widely processed and consumed in Indonesia and contain high antioxidants is cassava (*Manihot esculenta*). The part that is used as a source of antioxidants is the leaves. Cassava leaves contain phenolic phytochemical components, flavonoids, vitamin C, carotene, and iron as enzymatic antioxidant cofactors¹³⁻¹⁶. In addition, chlorophyll in cassava leaves also acts as an antioxidant which is a major barrier to oxidation reactions¹⁷. The content of vitamin C in cassava leaves almost reaches four times the content of vitamin C in cassava tubers, while the carotene content is only found in cassava leaves^{16,18}.

Antioxidant compounds in cassava leaves can provide electrons to free radicals which can inhibit chain reactions and stabilize free radical components^{13,14,16}. Therefore, administration of cassava leaves extract is expected to prevent liver damage caused by oxidative stress by gentamicin. If the liver damage can be prevented, the function of the liver in synthesizing albumin will not be disrupted. The effect of cassava leaves extract on serum albumin level in cases of hepatotoxicity has not been studied. Therefore, the authors will examine whether cassava leaves extract can prevent the decrease of serum albumin level in mice with gentamicin-induced hepatotoxicity.

Materials and Method

Cassava leaves used in this study were from Jember,

Indonesia. Cassava leaves were washed and dried in the sun. Simplisia dried leaves were mashed using a blender and then sieved until a fine powder is obtained which was then macerated using 70% ethanol solvent. Maceration results were processed into extracts using a rotary evaporator.

This study used a post test only control group design. As research subjects, 25 male mice (*Mus musculus*) aged 2-3 months and body weight ± 20 grams were divided into five random groups consisting of normal (N), control (K) with 80 mg gentamicin/kg b.w., treatment group 1 (P1) with gentamicin 80 mg/kg b.w. and cassava leaves extract 150 mg/kg b.w., treatment group 2 (P2) with gentamicin 80 mg/kg b.w. and cassava leaves extract 300 mg/kg b.w., and treatment group 3 (P3) with gentamicin 80 mg/kg b.w. and cassava leaves extract 450 mg/kg b.w. Gentamicin was peritoneally injected and cassava leaves were orally (p.o.) administered to the mice every day for 14 days.

The serum albumin level of mice was measured using the photometric method with a wavelength of 546 nm (DiaSys Diagnostic Systems). Data on serum albumin level of mice were analyzed using One Way Anova statistical test with a confidence level of 95%. Differences between groups were analyzed using the Post Hoc Tukey HSD test and the strength of the correlation between the dose of cassava leaves extract and serum albumin level of mice was analyzed using the Pearson correlation test.

Results

The serum albumin level of mice in the K group decreased compared to group N and the serum albumin levels of mice in the P1, P2, and P3 groups increased respectively (Figure 1). Analysis using the One Way Anova statistical test showed a significance value of 0,000 which meant that there were significant differences among groups. In the Post Hoc Tukey HSD statistical test, it can be seen differences between groups. Serum albumin level of mice between group N and group K showed sig. 0,000 which meant that administration of gentamicin 80 mg/kg b.w. for 14 days significantly decreases serum albumin level in mice. Serum albumin level of mice between groups K and P1 and groups K and P2 did not show significant differences (sig. 0.222 and 0.076). Cassava leaves extract 150 mg/kg b.w. and 300 mg/kg b.w. for 14 days prevent the decrease of serum albumin level in mice but not significant. Significant

differences were found between groups K and P3 (sig. 0.016) which meant that the administration of cassava leaves extract 450 mg/kg b.w. for 14 days could prevent significant the decrease of serum albumin level in mice.

However, serum albumin level of mice between groups P2 and N and groups P3 and N did not show significant differences (sig. 0.051 and 0.208). Pearson correlation test resulted an R value of 0.627.

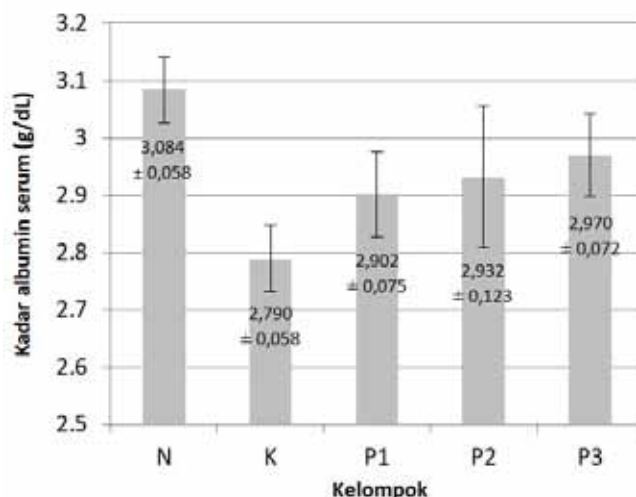


Figure 1. Mice serum albumin levels

N: normal group, K: control group (gentamicin 80 mg/kg b.w. i.p. for 14 days), P1: treatment group 1 (gentamicin 80 mg/kg b.w. i.p. and cassava leaves extract 150 mg/kg b.w. p.o. for 14 days), P2: treatment group 2 (gentamicin 80 mg/kg b.w. i.p. and cassava leaves extract 300 mg/kg b.w. p.o. 14 days), P3: treatment group 3 (gentamicin 80 mg/kg b.w. i.p. and cassava leaves extract 450 mg/kg b.w. p.o. for 14 days).

Discussion

Administration of gentamicin at dose of 80 mg/kg b.w. i.p. for 14 days reduced serum albumin level in mice ($p < 0.05$). In another study, administration of gentamicin 100 mg/kg b.w. every other days for 21 days also significantly reduced rat albumin level³. Albumin is a protein found in the highest amount in plasma. Albumin plays an important role in maintaining plasma osmotic pressure and acts as an endogenous and exogenous transporter¹⁹. Albumin is synthesized by the liver and excreted rapidly into the circulatory system so that if there is a liver injury, its level in the blood will decrease^{4,19}. Increased intracellular enzymes of ALT and AST liver and albumin depletion reflect liver or hepatocyte damage³.

In this study, decreased albumin level was caused by

gentamicin-induced hepatotoxicity. In previous studies, the average score of hepatocyte damage in the gentamicin-induced mice group showed significant differences with the normal mice group ($p < 0.05$). The results of liver microscopic observations due to gentamicin induction are parenchymal degeneration, hydropic degeneration, and necrosis²⁰. The characteristics of hepatocytes undergoing parenchymous degeneration are swollen cells, cloudy cytoplasm and granular; characteristics of hepatocytes undergoing hydropic degeneration are visible vacuoles in the cytoplasm and pale cytoplasm; the characteristics of hepatocytes undergoing necrosis are shrinking cell nuclei (picnosis), cell nuclei breaking into fragments (karyokinesis), lysis cell nuclei (karyolysis), and lysis cell membranes^{5,8,21}. Hepatocyte necrosis is classified as zonal necrosis which is generally found in zone 3 and can also be found in zone 1^{22,23}. In another study, administration of gentamicin 80 mg/kg b.w. for seven days showed hepatocyte necrosis, widening of sinusoids, vacuole formation in hepatocytes, and leukocyte infiltration¹².

Gentamicin use slightly above the therapeutic dose has the potential to cause hepatotoxicity. About 5-10% of patients treated with gentamicin have liver damage¹². Many studies have examined the effect of gentamicin on

changes in levels of intracellular antioxidant enzymes such as superoxide dismutase (SOD), glutathione (GSH), and catalase and changes in level of lipid peroxidation products such as malondialdehyde (MDA). Administration of gentamicin 100 mg/kg b.w. i.p. every other days for 21 days significantly reduced SOD and GSH levels and increased MDA level in rat liver³; gentamicin 100 mg/kg b.w. i.p. for seven days decreased GSH level and significantly increased MDA level in rat liver¹¹; gentamicin 100 mg/kg b.w. i.p. for three days significantly reduced levels of GSH, SOD, and liver catalase in mice¹; gentamicin 40 mg/kg b.w. i.p. for seven days can significantly reduce GSH and increase MDA in rat liver².

Cassava leaves are used as a source of natural antioxidants that can provide protection against cells from the influence of free radicals. The leaves contain carotene which is the most active provitamin A and high in vitamin C (7052 µg carotene and 130 mg of vitamin C every 100 grams)^{15,18,25}. Carotene and vitamin C are classified as exogenous non-enzymatic secondary antioxidants that can capture free radicals and prevent chain reactions in lipid peroxidation^{15,16,26,27}. Antioxidant compounds provide electrons to free radical molecules resulting them as stable molecules^{13,14}.

A study analyzing the phytochemical components of methanol extract and water extracts of boiled cassava leaves and simplicia showed the presence of flavonoids and phenolic compounds in cassava leaves. These compounds are also classified as secondary antioxidants. Flavonoids are polyphenol compounds with phenolic hydroxyl groups that make them have antioxidant activity by inhibiting the activity of superoxide anions, lipid peroxide radicals, and hydroxyl radicals^{16,26,27}. As the leaves grow older, the flavonoid levels increase¹⁷. Cassava leaves extract used in this study was not processed by boiling. Processing cassava leaves by boiling reduces levels of phenolic compounds and flavonoids by 30%. Phenolic and flavonoid compounds are unstable so that they are easily damaged by heating during the boiling process¹³. In addition, the carotene can also be damaged by heating²⁵. Plants with green leaves contain iron which can act as a co-factor of intracellular antioxidant enzymes, namely catalase which functions as a catalyst for the chemical reaction of hydrogen peroxide into water^{14,26,28}. Chlorophyll in cassava leaves is also a major barrier to oxidation reactions. Chlorophyll level will increase with increasing time until the leaves develop fully and then decrease in old leaves¹⁷.

The serum albumin level of mice in the group administered gentamicin and cassava leaves extract 450 mg/kg b.w. were significantly different compared to the group of mice that were administered gentamicin without cassava leaves extract. However, serum albumin level of mice in the group that was administered cassava leaves extract 300 mg/kg b.w. was not different from the normal group. This indicated that cassava leaves extract 300 mg/kg b.w. could prevent the decrease of serum albumin level so that it was equal to normal serum albumin level. R value of 0.627 (0.6- <0.8) in the Pearson correlation test showed a strong correlation between the dose of cassava leaves extract and serum albumin level in mice. A positive R value means that the dose of cassava leaves extract and serum albumin level of mice are directly proportional. The higher the dose of cassava leaves extract, the higher the serum albumin level of mice²⁹.

Conclusion

From the results of this study, it can be concluded that cassava leaves extract prevents the decrease of serum albumin level in mice with gentamicin-induced hepatotoxicity.

Ethical Clearance: Ethical Committee for Research, Faculty of Medicine, University of Jember, Jember, East Java, Indonesia.

Source of Funding: Self-funding

Conflict of Interest: Nil

References

1. Chandel SS, Sahu RK. Protective Effect of Dietary Inclusion of Aegle marmelos fruit on gentamicin-induced hepatotoxicity in rats. *Int J Green Pharm* 2017; 11: 597–603.
2. Almohawes ZN. Protective Effect of Melatonin on Gentamicin Induced Hepatotoxicity in Rats. *J Pharmacol Toxicol* 2017; 12: 129–135.
3. Galaly SR, Ahmed OM, Mahmoud AM. Thymoquinone and Curcumin Prevent Gentamicin-Induced Liver Injury by Attenuating Oxidative Stress, Inflammation and Apoptosis. *J Physiol Pharmacol* 2014; 65: 823–832.
4. Guyton, Hall. *Guyton and Hall Textbook of Medical Physiology*. 12th ed. Singapore: Elsevier Inc., 2011.

5. Prasetiawan E, Sabri E, Ilyas S. Gambaran Histologis Hepar Mencit (*Mus musculus* L.) Strain DDW setelah Pemberian Ekstrak N-Heksan Buah Andaliman (*Zanthoxylum acanthopodium* DC.) selama Masa Pra Implantasi dan Pasca Implantasi. *Saintia Biol* 2015; 1: 1–6.
6. Fisher K, Vuppalanchi R, Saxena R. Drug-Induced Liver Injury. *Arch Pathol Lab Med* 2015; 139: 876–887.
7. David S, Hamilton JP. Drug-Induced Liver Injury. *Natl Institutes Heal Public Access* 2010; 6: 73–80.
8. Istikhomah, Lisdiana. Efek Hepatoprotektor Ekstrak Buah Pepada (*Sonneratia caseolaris*) pada Tikus Putih (*Rattus norvegicus*). *Unnes J Life Sci* 2015; 1: 1–8.
9. Licata A, Minissale MG, Calvaruso V, et al. A Focus on Epidemiology of Drug-Induced Liver Injury: Analysis of a Prospective Cohort. 2017; 21: 112–121.
10. Björnsson ES. Global Epidemiology of Drug-Induced Liver Injury (DILI). *Curr Hepatol Reports* 2019; July 16: 1–6.
11. Khaksari M, Esmaili S, Abedloo R, et al. Palmatine Ameliorates Nephrotoxicity and Hepatotoxicity Induced by Gentamicin in Rats. *Arch Physiol Biochem* 2019; June 26: 1–6.
12. Noorani AA, Gupta KA, Bhadada K, et al. Protective Effect of Methanolic Leaf Extract of *Caesalpinia bonduc* (L.) on Gentamicin-Induced Hepatotoxicity and Nephrotoxicity in Rats. *Iran J Pharmacol Ther* 2011; 10: 21–25.
13. Hasim, Falah S., Dewi L.K. Effect of Boiled Cassava Leaves (*Manihot esculenta* Crantz) on Total Phenolic, Flavonoid and its Antioxidant Activity. *Curr Biochem* 2016; 3: 116–127.
14. Normasari R, Dewi R, Rachmania S. Efek Ekstrak Daun Singkong terhadap Perbaikan Struktur dan Fungsi Ginjal Mencit yang Diinduksi Gentamisin. *J Agromedicine Med Sci* 2017; 3: 1–6.
15. Obeten KE, Odey SA, Udo-Affah G, et al. Effect of Aqueous Extract of Cassava (*Manihot esculenta*) Leaf on The Morphology and Micro-Anatomy of The Liver of Wister Rats. *Int J Anat Res* 2017; 5: 4031–4035.
16. Rachman F, Hartati S, Sudarmonowati E, et al. Aktivitas Antioksidan Daun dan Umbi dari Enam Jenis Singkong (*Manihot utilissima* Pohl). *Biopropal Ind* 2016; 7: 47–52.
17. Solikhah R., Purwantoyo E, Rudyatmi E. Aktivitas Antioksidan dan Kadar Klorofi Kultivar Singkong di Daerah Wonosobo. *Life Sci* 2019; 8: 86–95.
18. Depkes. Daftar Komposisi Bahan Makanan. Jakarta: Bharata Karya Aksara, 1995.
19. Moman RN, Varacallo M. Albumin Physiology. NCBI Bookshelf; January, <https://www.ncbi.nlm.nih.gov/books/NBK459198/>(2018).
20. Dewi R, Normasari R. Protective Effect of Cassava Leaf Extract on Gentamicin-Induced Hepatotoxicity In Mice. *J Agromedicine Med Sci* 2019; 5: 168–173.
21. Sari WN, Saebani, Dhanardhono T. Pengaruh Pemberian Butylated Hydroxytoluene (2,6-Di-Tert-Butyl-4-Methylphenol) Per Oral Dosis Bertingkat terhadap Gambaran Histopatologis Ginjal. *J Kedokt Diponegoro* 2018; 7: 1344–1357.
22. Krishna M. Patterns of Necrosis in Liver Disease. *Clin Liver Dis* 2017; 10: 53–56.
23. Kleiner DE. Recent Advances in the Histopathology of Drug-Induced Liver Injury. *Surg Pathol Clin* 2018; 11: 297–311.
24. Winarsi H. Antioksidan Alami dan Radikal Bebas: Potensi dan Aplikasinya dalam Kesehatan. Yogyakarta: Kanisius, 2007.
25. Meiliana, Roekistiningsih, Sutjiati E. Indonesian Journal of Human Nutrition. *Indones J Hum Nutr* 2014; 1: 23–34.
26. McDowell LR, Wilkinson N, Madison R, et al. Vitamins and Minerals Functioning as Antioxidants with Supplementation Considerations. *Proceeding Florida Rumin Nutr Symp*, dairy.ifas.ufl.edu/rns/2007/McDowell.pdf (2007).
27. Samber LN, Semangun H, Prasetyo B. Karakteristik Antosianin sebagai Pewarna Alami. *Pros Semin Nas X Pendidik Biol FKIP UNS* 2013; 10: 1–4.
28. Liu RM, Pravia KAG. Oxidative Stress and Glutathione in TGF- β -Mediated Fibrogenesis. *Free Radic Biol Med* 2010; 48: 1–15.
29. Dahlan MS. Statistik untuk Kedokteran dan Kesehatan. 6th ed. Jakarta: Epidemiologi Indonesia, 2014.