

Postmortem Computed Tomography Imaging and Autopsy in Penetrating Neck Injury Case: A Comparative Study

Babulal Chaudhary^{1,2}, Ankit Kumar³, Pankaj Sharma⁴,
Abhishek Yadav⁵, Rishi Sharma^{6*}

¹Professor, Department of Forensic Medicine and Toxicology, All India Institute of Medical Sciences (AIIMS), Rishikesh-249203, Uttarakhand, India.

²Medical Director, Deen Dayal Upadhyay Hospital (DDUH), New Delhi-110064, India.

³Senior resident, Department of Forensic Medicine and Toxicology, All India Institute of Medical Sciences (AIIMS), Rishikesh-249203, Uttarakhand, India.

⁴Associate professor, Department of Radiodiagnosis and Imaging, All India Institute of Medical Sciences (AIIMS), Rishikesh-249203, Uttarakhand, India.

⁵Additional professor Department of Forensic Medicine and Toxicology, All India Institute of Medical Sciences (AIIMS), New Delhi-110029, Delhi, India.

⁶PhD Scholar, Department of Forensic Medicine and Toxicology, All India Institute of Medical Sciences (AIIMS), Rishikesh-249203, Uttarakhand, India.

How to cite this article: Babulal Chaudhary, Ankit Kumar, Pankaj Sharma, Abhishek Yadav, Rishi Sharma et al
Postmortem Computed Tomography Imaging and Autopsy in Penetrating Neck Injury Case: A Comparative Study.
Volume 22 | Number 3 | July-September 2022

Abstract:

Objective: This study compares and contrasts traditional autopsy with postmortem computed tomography in a homicide case of penetrating neck injury.

Method: Autopsy and postmortem computed tomography (PMCT) findings were compared.

Results: PMCT demonstrates the presence of air embolism, surgical emphysema, the direction of the wound, entry, and weapon trajectory. Autopsy proved helpful in terms of external examination.

Conclusion: PMCT was superior to the internal inspection at autopsy in the presented case and has added value for detecting additional findings regarding the cause of death. However, a combination of both techniques increases the quality of postmortem evaluation.

Keywords: Virtopsy; virtual autopsy; neck injury; stab; postmortem imaging; postmortem examination

Introduction:

Computed Tomography (CT) is gaining popularity as a diagnostic imaging technique in medicolegal autopsies and forensic examinations. Postmortem

Computed Tomography (PMCT) is now widely accepted¹ and adopted in several countries². PMCT has been used extensively worldwide for more than a decade³⁻⁶. In England and Wales, the public has a right to request PMCT as an alternative to autopsy⁷.

*Corresponding Author : Rishi Sharma

Department of Forensic Medicine and Toxicology
All India Institute of Medical Sciences (AIIMS),
Rishikesh-249203, Uttarakhand, India.
Email: sharmarishi1991@yahoo.com

Multislice CT performs the virtual autopsy and provides 3D reconstruction with higher resolution and better image quality. PMCT is exceptionally beneficial to track the trajectory of a weapon or the path of a bullet through the body and helps reconstruct the event⁸. It is critical to consider the advantages and limitations of PMCT, particularly image interpretation.

PMCT advantages

- Extremely sensitive in detecting fractures (facial bones, atlas/axis, scapular, and cervical), intraventricular hemorrhage, and pneumothorax^{9,10} skull base, facial bones and atlas/axis.
- Ideal for visualizing bones (e.g., fracture pattern)^{11,12} avulsion of the neural arch from the vertebral body of the axis (C2, calcification within the brain parenchyma¹³, air/gas embolism¹⁴, acute hemorrhage, and tracheobronchial content¹⁵ the authors experienced discrepancies of tracheobronchial content findings between postmortem computed tomography (PMCT).
- Simple visualization of foreign objects (e.g., bullets) and their locations, as well as bullet trajectories¹⁶ localization of gunshot injury, caliber, and direction of the gunshot differentiating between entry and exit wound as well as associated injury to surrounding tissue. The results of both reader groups were compared to the each other and to autopsy findings considered as gold standard. Results: Reader groups I and II and as gold standard the autopsy evaluation showed in general a good correlation between all results. The overall discrepancy rate was 12/51 (23.4 %
- Ideally suited for burn-related cases¹⁷ to detect thermal fractures, heat injuries, extremity contraction and destruction, and thermal epidural hematoma.
- Identify critical findings in drowning cases (e.g. hemodilution, paranasal and tracheal fluid collection, emphysema aquosum)¹⁸.

- Used to aid in identification in the event of a mass disaster.
- In the current coronavirus pandemic scenario, it will also aid in reducing coronavirus infection spread among mortuary staff and forensic experts.
- There is a significantly reduced risk of infection transmission to the healthcare worker.
- Facial reconstruction and 3D volume rendering are possible in the case of mutilated body.
- Non-invasive preserves the integrity of the corpse, fast acquisition.
- Multiple analyses are possible with digital data storage.

Limitations

- Limited visualization of soft tissue
- Artifacts (e.g., prosthetics, valves, and implants)
- Not available at all centres and associated costs
- Interpretation of PMCT images requires trained professionals.
- Poor sensitivity to detect external injuries such as bruises, superficial lacerations, and abrasions.

Indian researchers recently published a comparative study of traditional autopsy and PMCT in traumatic death cases, concluding that conventional autopsy remains superior to PMCT¹⁰ traditional autopsy (TA. The difficulty of PMCT detecting external findings has been mentioned repeatedly. Not only incised wounds or lacerations are essential to the medicolegal appreciation of a case, but also very superficial abrasions and hematomas or petechial hemorrhages, etc., findings that PMCT cannot detect. In this study, we present a homicidal penetrating neck injury in which PMCT scans were performed before the conventional autopsy, and this study aims to highlight whether PMCT provides additional information regarding the cause of death.

Method

A 26-year-old female was stabbed in the neck during a physical assault. The victim was rushed to AIIMS Rishikesh, where she was declared dead on arrival. All necessary paperwork and inquest procedure were completed. We performed a full-body PMCT examination approximately three hours after death. Immediately following the PMCT examination, the conventional autopsy was performed. The body was scanned supine with arms adjacent to the body while still sealed and wrapped. The body was scanned on a Philips 64-slice CT installed in the Department of Radiodiagnosis at AIIMS trauma centre using the following parameters: 1.5 x 40 collimation, 120 kV, and pitch 1.2 rotation time of 1 second. The acquisition time was 42 seconds for body volume imaging (including the lung), and images were reconstructed with a 1.5 mm slice thickness, 0.5 mm gap, and a smooth filter.

A board-certified radiologist performed image processing and interpretation. Both the forensic and radiologist experts were unaware of each other's findings. Multiplanar reconstructions and 3D volume rendering tools were used to analyze the images. CT was performed with the necessary ethical clearance from the institutional ethics committee, while family consent was not required in this case. Forensic experts unaware of the PMCT findings carried out the medicolegal autopsy.

Results

Observations from Postmortem Computed Tomography (PMCT)

CT results are comparable to those of a conventional autopsy. However, specific PMCT findings added to the overall picture. On the left side of the neck to the front (trajectory of the wound), below the hyoid bone, we observed a breach in the subcutaneous tissue (Fig 1 A). Hyoid bone and thyroid cartilage were unremarkable. The tracheal defect was continuous with the subcutaneous plane. A suspicious defect was observed in the anterior aspect of the esophagus at the D1/D2 vertebral level. Air embolism was discovered in vascular structures, most notably in the brachiocephalic artery, proximal part of the right

subclavian artery, and internal carotid artery (Fig 1 B). Emphysema was noted in the anterior wall of the larynx and neck, involving posterior paraspinal muscles on the right side (Fig 1 C), following the stab wound that pierced the skin, subcutaneous tissue, neck muscles, and neck internal carotid artery (Figure 2B, injury 3). Stab wound piercing the chest cavity (2.26 cm depth) resulting in right side hemothorax (Figure 1 D). Air embolism was found in the right ventricle (Fig 1 E), bilateral subclavian vein, and right superior vena cava (Fig 1 F). PMCT images also enable reconstruction of the weapon trajectories (in this case, knife) used for the assault like that described in conventional autopsy reports. The wound on the anterior part of the left side of the neck, touching the midline at the level of the D1 vertebra, is visible in a volume-rendered PMCT image (Fig 1 A). On CT, the presence of air embolism, irregularities in the skin, increased emphysema volume, and increased density indicates penetrating injury. After interpreting the images, we determined that a hemorrhage and traumatic air embolism caused the death.

Observations from conventional autopsy

In a conventional autopsy, major external injuries (Figure 2) were described in greater detail. On the right side of the face and neck, respectively, there was an incised wound measuring 12.5 x 0.4 cm and 7 x 0.4 cm (Fig 2A, Injury 1). A stab wound of size 4 x 0.5 x 4.5 cm was present on the left side of neck with the wound track going deep, cutting the internal carotid artery (Fig 2B, Injury 3). Incised wound of size 14.5 x 0.5 cm located horizontally on the left side of the neck and extending to the back of the neck (Fig 2C, Injury 4).

Multiple incised and stab wounds were described in 31 external antemortem injuries. The track of the wounds, their direction, and the type of probable weapon—a single or double-edged weapon—were all detailed to assist the investigating officer in reconstructing the crime scene during the investigation and court proceedings. Each internal organ was dissected and showed pallor of internal organs or even subendocardial hemorrhages, indicating severe blood loss. The cause of death declared by conventional autopsy was hemorrhagic shock due to injury to the vital structure of the neck.

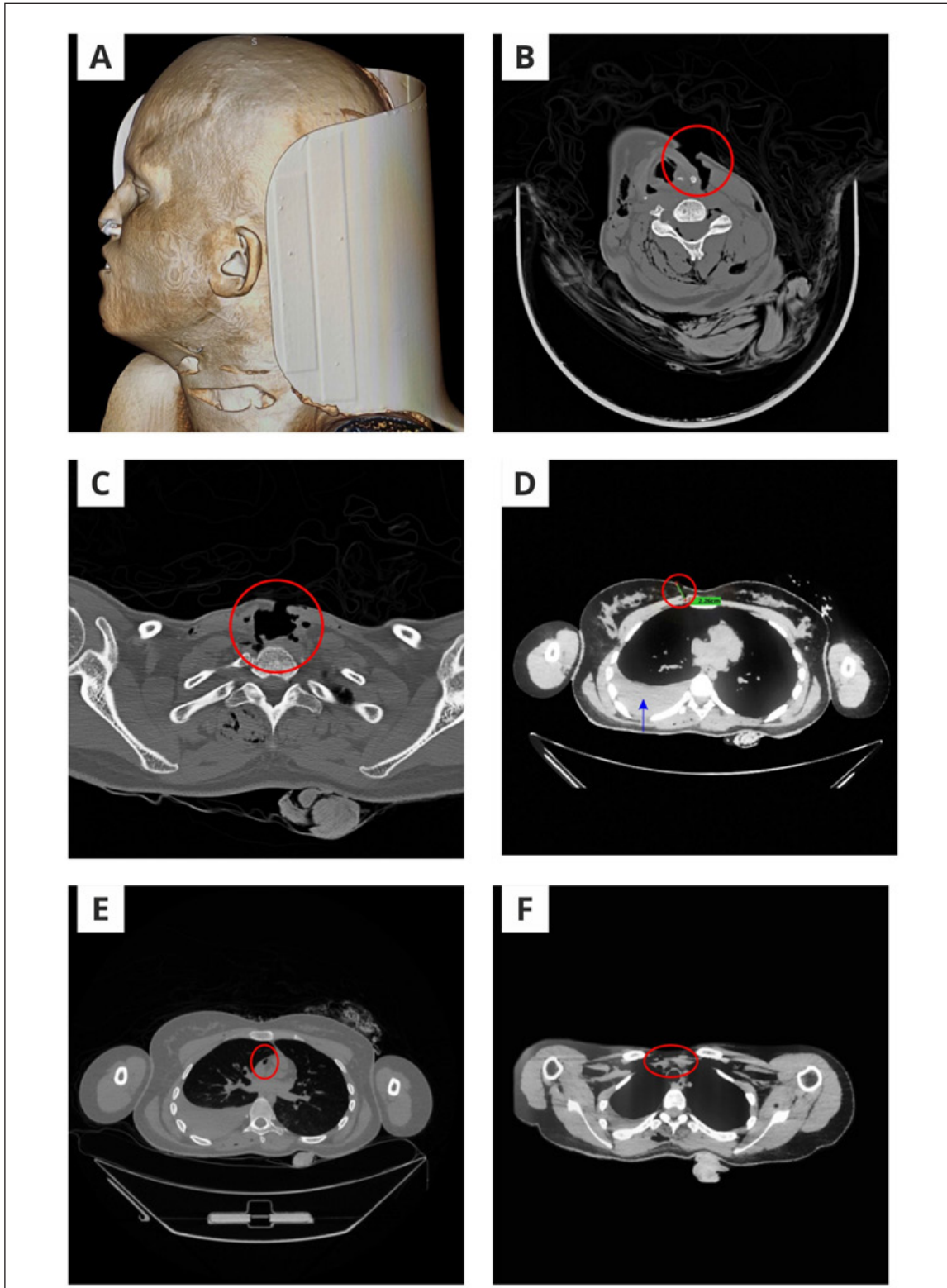


Figure 1. PMCT images, (A) Multiple breaches in skin and subcutaneous tissue of neck suggestive of an incised wound; (B) presence of air due to stab wound piercing the neck skin/subcutaneous tissue/ muscles and internal carotid artery; (C) Presence of air (red circle) due to breach in anterior wall of larynx and soft tissue; (D) Stab wound piercing chest cavity and black area in muscle shows air entering through wound with depth measurements with associated right side hemothorax (white area, blue arrow); (E) Air in the ventricle (red circle); (F) Black area inside red circle showing air in the vessels.

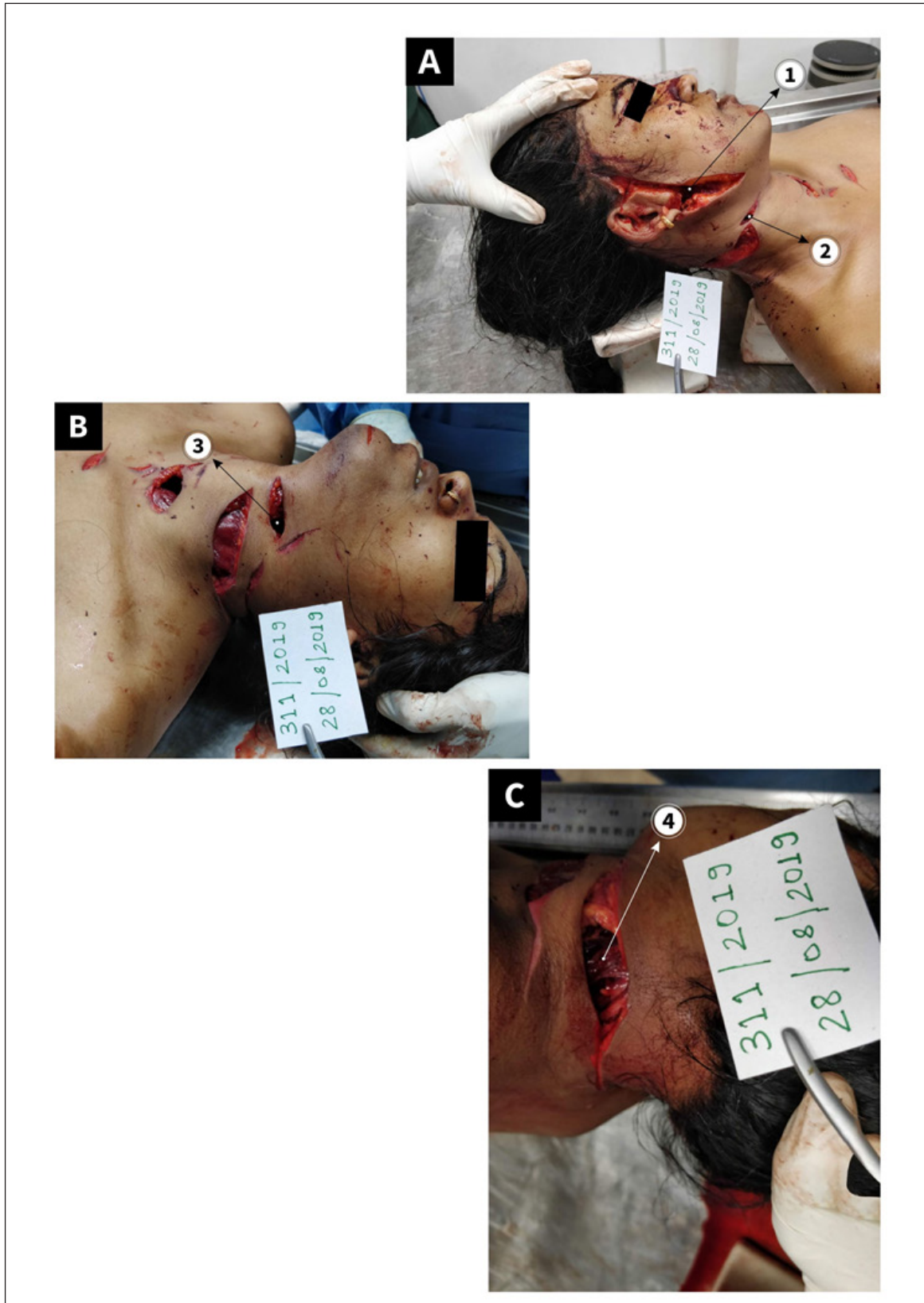


Figure 2. Autopsy appearance (A) injury no (1) incised wound over the right side of the face, injury no (2) incised wound over the right side of neck, (B) incised wound; injury no (3) stab wound over the left side of neck cutting internal carotid artery, (C) Injury no (4) incised wound present over left side of neck extending to the back of neck.

Discussion

In several countries, a thorough external inspection of the body at the scene, in conjunction with police investigation results, augmented with PMCT is sufficient for the district attorney. Occasionally, a toxicological screening (blood and urine) of different substances can be performed if one wants to exclude with reasonable certainty a drug-related death or incapacitation due to such substances. In India, the current legal system only accepts the postmortem report conducted by the traditional method, but the government has proposed adopting the virtual autopsy procedure in its legal system. The current case demonstrates how imaging can be a valuable tool in forensic examinations to ascertain the cause of death. PMCT has a higher sensitivity for detecting abnormalities in locations that are difficult to access during the conventional autopsy; it can significantly aid conventional autopsy in exceptional circumstances, such as tracing bullet trajectories or determining the direction of impact if circumstances allow for autopsy waiver.

Our study is unique as it presents PMCT and autopsy findings separately, allowing a gold standard to be created independently. Gas embolism is extremely difficult to detect during autopsy and is frequently overlooked^{19,20} by forensic experts, and non-description of air embolism is quite common²¹. In this case, vascular injury and air embolism were better identified during internal examination by PMCT; this outcome is consistent with a previous report by Schnider et al²¹. The likelihood of detecting subcutaneous emphysema during conventional autopsy is almost nil^{22,23} 40 forensic cases were examined and findings were verified by subsequent autopsy. Results were classified as follows: (I. This particular feature of PMCT outperforms conventional autopsy in this case.

Approximately 15-25% of penetrating injuries to the neck result in an arterial injury, involving the carotid arteries (80%) and vertebral arteries (43%)²⁴. In this case, PMCT discovered gas embolism in vital vascular structures such as the subclavian and common carotid arteries, implying that vascular air embolism was the primary cause of death. The conventional autopsy determined that the deceased died of hemorrhagic shock caused by injury to the neck's vital vascular structure, the internal carotid artery.

In our case, postmortem CT was of great help in identifying the wound course, the trajectory of the weapon (knife) Fig 1A, and vascular injuries. Determining the trajectory of the wound track aids in the evaluation of patients with penetrating neck trauma. However, the trajectory of penetrating injuries is often difficult to determine clinically because wound tracks often are not oriented in standard axial, sagittal, and coronal planes; liberal use of an interactive viewer to manipulate the dataset is essential to appreciate the true orientation of the neck. Although, In this case, due to PMCT, we can predict the cause of death and the trajectory of the wound track (Fig 1A) before the traditional autopsy, unable to determine the sequence of stab wound injury as multiple stab wounds were present on the victim's body.

Conclusion

We conclude that PMCT can have added value for detecting additional findings regarding the cause of death. However, PMCT and conventional autopsy will undoubtedly improve the diagnostic quality, reporting, and documentation of medicolegal autopsy reports. It is best used in conjunction with traditional autopsy rather than as a substitute for it recommended by forensic and radiology experts²⁵. PMCT provides more precise information than a traditional autopsy, but PMCT should, as in the case of autopsy (meaning the internal examination), never be used as a single method²⁶. The authors are adamant that the conventional autopsy approach is still necessary for investigation, particularly concerning the external examination. Image analysis was used to demonstrate the presence of gas embolism, subcutaneous emphysema, vascular injury, and weapon trajectory. PMCT should not be reported separately, and imaging findings must be interpreted based on possibilities, with the subject expert doing a detailed review of case history, medical history, and external examination.

Future recommendation

We believe that collaboration between radiologists and forensic pathologists on expertise, knowledge, interpretation, and technical pitfalls could help virtual autopsy become a highly accurate procedure

preceding standard autopsy. PMCT can be used in place of conventional autopsies in certain circumstances and is also an excellent complement in most cases. In the future, PMCT angiography method could be suggested for such cases, considering the presence of vascular injuries, which cannot be visualized by native PMCT. To summarize, one should first recognize the advantages and disadvantages of each approach before implementing the integrated procedure.

Ethical approval

This project has been reviewed and approved by the institutional ethical committee (AIIMS/IEC/19/945)

Funding: This research received funding from institutional intramural research grant (253/IEC/IM/2019).

Conflict of Interest: None

References

1. Poulsen K, Simonsen J. Computed tomography as routine in connection with medico-legal autopsies. *Forensic Sci Int.* 2007 Sep 13;171(2-3):190-7.
2. Bolliger SA, Thali MJ, Ross S, Buck U, Naether S, Vock P. Virtual autopsy using imaging: Bridging radiologic and forensic sciences. A review of the Virtopsy and similar projects. *Eur Radiol.* 2008 Feb;18(2):273-82.
3. Aghayev E, Thali M, Jackowski C, Sonnenschein M, Yen K, Vock P, et al. Virtopsy-Fatal Motor Vehicle Accident with Head Injury. *J Forensic Sci.* 2004;49(4):1-5.
4. Thali MJ, Kneubuehl BP, Vock P, Allmen GV, Dirnhofer R. High-speed documented experimental gunshot to a skull-brain model and radiologic virtual autopsy. *Am J Forensic Med Pathol.* 2002 Sep;23(3):223-8.
5. Jacobsen C, Lynnerup N. Craniocerebral trauma - Congruence between post-mortem computed tomography diagnoses and autopsy results. A 2-year retrospective study. *Forensic Sci Int.* 2010 Jan 30;194(1-3):9-14.
6. Thali MJ, Yen K, Plattner T, Schweitzer W, Vock P, Ozdoba C, et al. Charred Body: Virtual Autopsy with Multi-slice Computed Tomography and Magnetic Resonance Imaging. *J Forensic Sci.* 2002;47(6):1556-9.
7. Ruttu GN, Morgan B, Robinson C, Raj V, Pakkal M, Amoroso J, et al. Diagnostic accuracy of post-mortem CT with targeted coronary angiography versus autopsy for coroner-requested post-mortem investigations: a prospective, masked, comparison study. *Lancet (London, England).* 2017;390(10090):145.
8. Del Fante Z, De Matteis A, Fazio V, Di Fazio N, Quattrocchi A, Romano S, et al. The importance of post mortem computed tomography (PMCT) in the reconstruction of the bullet trajectory. *Clin Ter.* 2019;170(2):E129-33.
9. Legrand L, Delabarde T, Souillard-Scemama R, Sec I, Plu I, Laborie JM, et al. Comparison between postmortem computed tomography and autopsy in the detection of traumatic head injuries. *J Neuroradiol.* 2020 Feb 1;47(1):5-12.
10. Mishra B, Joshi M, Lalwani S, Kumar A, Kumar A, Kumar S, et al. A comparative analysis of the findings of postmortem computed tomography scan and traditional autopsy in traumatic deaths: Is technology mutually complementing or exclusive? *Arch Trauma Res.* 2018;7(1):24.
11. Hayashi T, Hartwig S, Tsokos M, Oesterhelweg L. Postmortem multislice computed tomography (pmMSCT) imaging of hangman's fracture. *Forensic Sci Med Pathol.* 2014 Mar 6;10(1):3-8.
12. Jacobsen C, Bech BH, Lynnerup N. A comparative study of cranial, blunt trauma fractures as seen at medicolegal autopsy and by Computed Tomography. *BMC Med Imaging.* 2009 Oct 16;9(1):18.
13. Deng H, Zheng W, Jankovic J. Genetics and molecular biology of brain calcification. Vol. 22, *Ageing Research Reviews.* Elsevier Ireland Ltd; 2015. p. 20-38.
14. Zerbini T, Zerbini T, Da Silva LFF, Gonçalves Ferro AC, Uliana Kay F, Junior EA, et al. Differences between postmortem computed tomography and conventional autopsy in a stabbing murder case. *Clinics.* 2014 Dec 1;69(10):683-7.
15. Zech WD, Jackowski C, Schwendener N, Brencicova E, Schuster F, Lombardo P. Postmortem CT versus forensic autopsy: frequent discrepancies of tracheobronchial content findings. *Int J Legal Med.* 2016;130(1):191-8.
16. Kirchhoff SM, Scaparra EF, Grimm J, Scherr M, Graw M, Reiser MF, et al. Postmortem computed tomography (PMCT) and autopsy in deadly gunshot wounds—a comparative study. *Int J Legal Med.* 2016 May 1;130(3):819-26.
17. Levy AD, Harcke HT, Getz JM, Mallak CT. Multidetector computed tomography findings in deaths with severe burns. *Am J Forensic Med Pathol.* 2009 Jun;30(2):137-41.
18. Christie A, Aghayev E, Jackowski C, Thali MJ, Vock P. Drowning - Post-mortem imaging findings by computed tomography. *Eur Radiol.* 2008 Feb;18(2):283-90.

19. Aghayev E, Yen K, Sonnenschein M, Jackowski C, Thali M, Vock P, et al. Pneumomediastinum and soft tissue emphysema of the neck in postmortem CT and MRI; a new vital sign in hanging? *Forensic Sci Int*. 2005 Oct 29;153(2-3):181-8.
20. Jackowski C, Thali M, Sonnenschein M, Aghayev E, Yen K, Dirnhofer R, et al. Visualization and Quantification of Air Embolism Structure by Processing Postmortem MSCT Data. *J Forensic Sci*. 2004 Nov 1;49(6):1-4.
21. Schnider J, Thali MJ, Ross S, Oesterhelweg L, Spendlove D, Bolliger SA. Injuries due to sharp trauma detected by post-mortem multislice computed tomography (MSCT): A feasibility study. *Leg Med*. 2009;11(1):4-9.
22. Thali MJ, Yen K, Schweitzer W, Vock P, Boesch C, Ozdoba C, et al. Virtopsy, a New Imaging Horizon in Forensic Pathology: Virtual Autopsy by Postmortem Multislice Computed Tomography (MSCT) and Magnetic Resonance Imaging (MRI)—a Feasibility Study. *J Forensic Sci*. 2003;48(2):2002166.
23. Ruder TD, Ketterer T, Preiss U, Bolliger M, Ross S, Gotsmy WF, et al. Suicidal knife wound to the heart: Challenges in reconstructing wound channels with post mortem CT and CT-angiography. *Leg Med*. 2011 Mar;13(2):91-4.
24. Saito N, Hito R, Burke PA, Sakai O. Imaging of penetrating injuries of the head and neck: Current practice at a level I trauma center in the united states. *Keio J Med*. 2014;63(2):23-33.
25. Cecchetto G, Bajanowski T, Cecchi R, Favretto D, Grabherr S, Ishikawa T, et al. Back to the Future - Part 1. The medico-legal autopsy from ancient civilization to the post-genomic era. Vol. 131, *International Journal of Legal Medicine*. Springer Verlag; 2017. p. 1069-83.
26. Bolliger SA, Thali MJ. Imaging and virtual autopsy: Looking back and forward. *Philos Trans R Soc B Biol Sci*. 2015;370(1674).