
Paraphilia Induced Suicide: A Case Report

Ashok Kumar Rastogi

Associate Professor, Forensic Medicine & Toxicology dept, All India Institute of Medical Science (AIIMS)
Patna, Bihar.

How to cite this article: Ashok Kumar Rastogi. Paraphilia induced suicide: A Case Report. Medico Legal Update / Volume 24 No 1, January-March 2024.

Abstract

Paraphilia is a term used to describe different sexual deviations involving unconventional methods of sexual gratification. Paraphiliacs indulged in abnormal and orthodox sex play by using objects as parts of the body or fantasies in which complete satisfaction is sought and obtained without sexual intercourse. Perversions are acts that are socially prohibited or unacceptable, or biologically undesirable. In sexual paraphilia, usually, person psychopaths suffer from mental aberrations and conflicts, socio-sexual maladjustments, psychosexual imbalance, and abnormalities. Paraphilia-induced suicide is a type of anomic suicide, and anomic suicide is due to a lack of social regulation that occurs during high levels of stress and frustration. Paraphilia may induce suicide even though paraphilia is not punishable. It is just due to fear of social defamation and social taboo.

Case presentation: A 59-year-old male committed suicide on the railway track, and then the body was sent to the mortuary room for an autopsy examination. History was taken from the police and relatives. He was a widower for the last 15 years.

Conclusions: Paraphilia is the form of the insertion of foreign bodies in the rectum, and when a person cannot remove foreign bodies himself, attending a hospital is very humiliating. To prevent the social integrity or self-esteem, the person committed suicide. Where this type of paraphilia is not listed as a crime in India, for sexual gratification, a person may use it by any means, which may be natural or unnatural form. Many unnatural forms of paraphilia are used by many people, which is not punishable. Sexual gratification is done by most of normal people and a few abnormal psychiatric people by any sexual perversion. All paraphilia that is not punishable by the law should not be considered a social taboo.

Keywords: Paraphilia, Anomic suicide, Sexual gratification

Background

Paraphilia is a term used to describe different sexual deviations involving unconventional methods of sexual gratification. Paraphiliacs indulged in abnormal and orthodox sex play by using objects as parts of the body or fantasies in which complete satisfaction is sought and obtained without sexual intercourse.

Perversions are acts that are socially prohibited or unacceptable, or biologically undesirable.⁽¹⁾ Paraphilia, which may be any form of action uranism, active algolagnia, necrophilia, necrophagic, passive algolagnia, fetichism, voyeurism, frotteurism, etc.⁽²⁾ In sexual paraphilia, usually, person psychopaths suffer from mental aberrations and conflicts, socio-sexual maladjustments, psychosexual imbalance,

Corresponding Author: Ashok Kumar Rastogi, Associate Professor, Forensic Medicine & Toxicology dept, All India Institute of Medical Science (AIIMS) Patna, Bihar.

E-mail: ashokforensic@yahoo.com, ashokforensic@gmail.com

Submission date: Nov 9, 2023

Revision date: Nov 23, 2023

Published date: Feb 14, 2024

and abnormalities. Durkheim identifies four different types of suicide which are egoistic suicide, altruistic suicide, anomic suicide, and fatalistic suicide. ⁽³⁾Paraphilia-induced suicide is a type of anomic suicide, and anomic suicide is due to a lack of social regulation that occurs during high levels of stress and frustration. A helpful categorization of rectal foreign bodies is that it classifies them into two categories: voluntary and involuntary, sexual and nonsexual.

Case presentation

A 59-year-old male committed suicide over a railway track collision by train, after a preliminary investigation by the investigating agency, the deceased was sent to the mortuary room for an autopsy examination. History was taken from the police and relatives. He was a widower for the last 15 years.

Autopsy examination findings:

Injuries:

1. Multiple abraded contusions over the anterior part of the Neck, face, chest, shoulder, and head region.
2. Multiple lacerations over the head region.
3. Various Skull bones were fractured at places.
4. Brain and meninges crushed in places.
5. Contusion over the right anterior part of the chest region.

Anal and rectum examination:

Except for a small tear of length 1.5cm at 08 o'clock position, over the rest anal opening, no evident external injury was appreciated, and the sphincter was found to have normal texture and tone.

After opening the abdomen, we feel some hard structure in the rectum. Then after making an incision over the rectum and examining the rectal cavity, we found a bottle gourd inside the lumen of the rectum. Measurement of foreign body bottle Gourd taken as length 24 cm in length and circumference was 08 cm. The bottlegourd was found intact, and no injury or contusion was appreciated inside the lumen of the rectum white mucoid material stuck at places over the gourd.

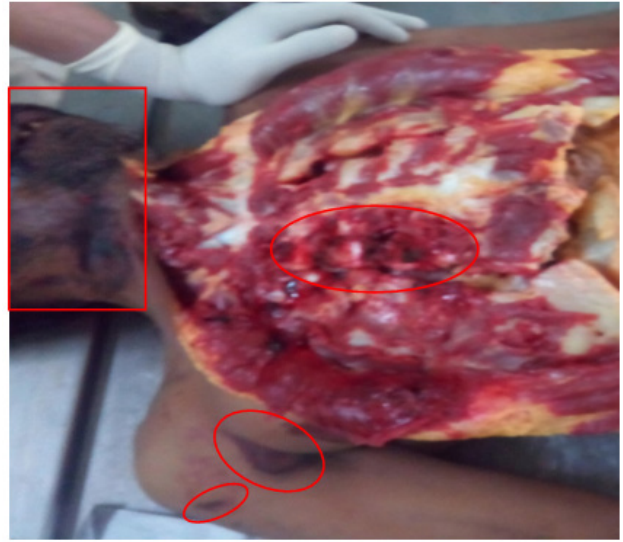


Figure 1: Injuries in form of abrasion and contusion seen in the red encircled area.

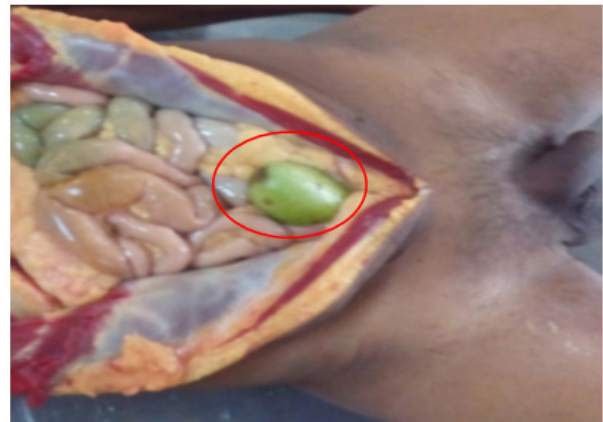

Figure 2: A green bottle gourd is in a circle in the rectum in red.

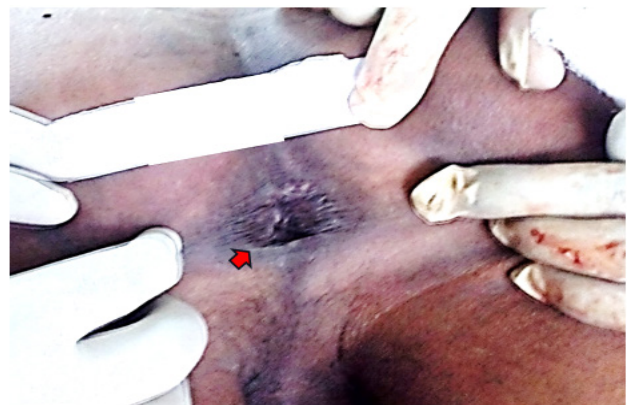

Figure 3: Anal opening observation one tear saw at 08 o'clock position indicated by the red arrow.



Figure 4: Recovered bottle gourd from the rectum.

Discussion

This case report is autopsy and history-based presentation. Sadism is an abnormal sexual behaviour where the person derives sexual excitement from inflicting psychological or physical pain on his sexual partner.⁽⁴⁾ Sexual gratification obtained or increased from acts of physical cruelty or infliction of pain upon one's partner. Insertion of a foreign body into the own rectum through the anus is cruelty to the self-body for sexual gratification. We can nomenclate it as Narcissistic Sadism.

In most cases, rectal foreign bodies are inserted for the erotic activity to get sexual gratification. The foreign bodies are commonly described as plastic or glass bottles, cucumbers, light bulbs, tube lights, axe handles, broomsticks, carrots, and wooden or rubber instruments.⁽⁵⁻⁷⁾

Other objects include dildoes or vibrators, light bulbs, candles, soda, or beer bottles.⁽⁸⁾ Some rectal foreign bodies, such as toothpicks, popcorn, bones etc. It may initially wallow, transit through the gastrointestinal tract, and be stuck in the rectum.⁽⁹⁾ Rectal foreign body cases are rarely reported and often related to sexual gratification, sexual assault or the result of ingestion and are rarely accidental.⁽¹⁰⁾ Insertion of foreign bodies in the rectum for sexual pleasure, primarily seen in males of the 3rd and 4th decades.⁽¹¹⁾ Such patients are ashamed and hesitant to visit the hospital.⁽¹²⁾ In India, it is a significant social taboo to fear losing social integrity if the patient has no courage to visit the hospital. The same fear happened in this case, and the patient committed suicide. The most common reason for a foreign body in the rectum was found to be purposefully inserted foreign body for sexual gratification in unnatural sexual behaviour.^(10,13)

Psychiatric patients also may insert foreign bodies in the rectum; Posttraumatic stress disorder patients insert foreign bodies in the rectum.⁽¹⁴⁾

Conclusions

Paraphilia is the form of the insertion of foreign bodies in the rectum, and when a person is unable to remove foreign bodies and attending hospital very humiliating for the person. To prevent the social integrity or self-esteem of the person who committed suicide. Where this type of paraphilia is not listed in crime in India. Sexual gratification person may be done by any means, which may be natural, or many unnatural forms of paraphilia are used by many people which is not punishable.

Sexual gratification is done by most the normal people and few the abnormal psychiatric people. Paraphilia that is not punishable by the law should not be considered a social taboo.

Acknowledgements: I would like to thank our mortuary employees.

Conflict of interest: Nil

Source of Funding: Non funded

Ethical Clearance: Not required Case report.

References

1. Reddy KSN. The essentials of forensic medicine and toxicology. 34 th ed. Hyderabad: K Suguna Devi; 2017. Chapter 18; Sexual offences: 402.
2. Agarwal Anil. Essentials of forensic medicine and toxicology. 1st ed. Avichal Publishing Company; 2016. 359-361 p.
3. Durkheim E. Suicide: The study of sociology. The New aork free press.; 1897.
4. Agarwal Anil. Forensic and Medico-legal Aspects of Sexual Crimes and Unusual Sexual Practices. New york: CRC Press,,taylor & Fracis group.; 2009. 167 p.
5. Singaporewalla RM, Tan DEL, Tan TK. Use of endoscopic snare to extract a large rectosigmoid foreign body with review of litera- ture. Surg Lapaprosoc Endosc Percutan Tech. 2007;17(2):145- 148.).
6. Akhtar MA, Arora PK. Case of unusual foreign body in rectum. Saudi J Gastroenterol. 2009;15(2):131- 132.
7. Goldberg JE, Steele SR. Rectal foreign bodies. Surgclin N Am. 2010; 90:173- 184.
8. <https://emedicine.medscape.com/article/776795-overview>.accessed on 26/06/2023.

-
9. Clarke D.L., Buccimazza I., Anderson F.A., et al. Colorectal foreign bodies. *Colorectal Dis.* 2005; 7:98-103.
 10. Coskun A, Erkan N, Yakan S, Yildirim M, Cengiz F. Management of rectal foreign bodies. *World J Emerg Surg.* 2013 Mar 13;8(1):11.
 11. Khan S, Khan S, Chalgari T, Akhtar R, Asad M, Kumar B. Case series: removal of rectal foreign bodies. *Cureus.* 2021 Feb 8;13(2):e13234.
 12. Goldberg JE, Steele SR. Rectal foreign bodies. *Surgclin N Am.* 2010;90:173- 184.
 13. Kokemohr P, Haeder L, Frömling FJ, Landwehr P, Jähne J. Surgical management of rectal foreign bodies: a 10- year single- center experience. *Innov Surg Sci.* 2017;2(2):89- 95.
 14. Sharif MR, Alizargar J. Self-insertion of a screwdriver into the rectum for sexual pleasure: A case report. *Australas J Paramed.* 2013;10(1).