

Aortic Rupture Due to Blunt Force Trauma: A Case Report

Pankaj Sahu¹, Nikhil Mehta², Niranjana Kumar Gunjan³

¹Postgraduate Student, ²Assistant Professor, ³Associate Professor, Department of Forensic Medicine and Toxicology, VCSGGIMS&R Srikot, Srinagar, Uttarakhand.

How to cite this article: Pankaj Sahu, Nikhil Mehta, Niranjana Kumar Gunjan. Aortic Rupture Due to Blunt Force Trauma: A Case Report. Medico Legal Update / Volume 24 No 1, January-March 2024.

Abstract

Background: Aortic rupture is one of the most important life-threatening conditions. Aortic rupture can occur by several causes, including trauma and spontaneous rupture.

Case Details: A 62-year-old man was brought for an autopsy examination in a mortuary with a history of road traffic accidents. As per history revealed by the police and relatives, the deceased was a retired army officer and was driving a car.

Autopsy Finding: The deceased was an elderly male. On external examination, the deceased sustained multiple reddish abraded contusions over the chest and both sides of the chest. On opening the thorax, the following injuries were present. Fracture of sternum was present at junction of body and manubrium associated with extravasations of blood in surrounding area. Multiple fracture of bilateral ribs associated with extravasations of blood in surrounding area.

Discussion: All aortic segments are prone to rupture following sudden blunt trauma. In various studies it is found that 92% of aortic rupture occur at isthmus followed by arch of aorta (4%) followed by ascending aorta (3%).

Keyword: Road traffic accidents, thoracic aorta, traumatic aorta rupture, rib fracture.

Introduction

Aortic rupture is one of the most important life-threatening conditions. Aortic rupture can occur by several causes, including trauma and spontaneous rupture. Trauma can result from blunt force impact, which cause by sudden and rapid deceleration, and/or penetrating injuries. Aortic rupture usually has a fatal outcome, since the aorta is a large vessel that contains blood with very high pressure, any trauma resulting in fast evacuation of blood from the vessels,

resulting in rapid haemorrhagic shock. Complete transection of aorta leading to exsanguination and immediate death. Traumatic aortic rupture is the second leading cause of death amongst victims of blunt chest trauma in motor vehicle accidents. 15% of fatalities involving motor vehicles are caused by traumatic aortic damage, and 85% of these deaths happen on the spot. All three aortic layers are typically affected by aortic disruptions, which typically occur transversely at the isthmus.^{1,2}

Corresponding Author: Nikhil Mehta Assistant Professor, Department of Forensic Medicine and Toxicology, VCSGGIMS & R Srikot, Srinagar, Uttarakhand.

E-mail: spankaj680@gmail.com

Mobile No: 9354234261

Submission date: May 6, 2023

Revision date: September 27, 2023

Published date: Feb 14, 2024

Case Details

A 62-year-old man was brought for an autopsy examination in a mortuary with a history of road traffic accident. As per history revealed by the police and relatives, the deceased was a retired army officer and was driving a car. While driving, his car collided with a lorry coming from the opposite direction, and he was seriously injured and was brought to the Emergency Department of H.N.B base hospital Srikot, Srinagar U.K, a Tertiary care Centre where he was declared brought dead.

Autopsy Finding

- The deceased was elderly male. On external examination, the deceased sustained multiple reddish abraded contusions over the chest and both sides of the chest. On opening the thorax, following injuries were present:
 1. Sternum fracture was present at the junction of body & manubrium associated with extravasations of blood in surrounding area.
 2. Multiple fracture of bilateral ribs associated with extravasation of blood in surrounding area.
 3. Multiple contusions and lacerations of varying sizes were present over the both lungs.
 4. Complete transection of aorta at isthmus region was present.
 5. Pericardium was ruptured.
 6. Approximately 500ml of frank blood was present in thoracic cavity.
- In abdominal cavity multiple lacerations were present over the liver and peritoneal cavity was filled with approximately 1000 ml of liquid and clotted blood. Organs were pale in appearance.
- The cause of death in this case was opined as haemorrhage and shock, secondary to blunt force trauma to the chest and abdomen.

Discussion

All aortic segments are prone to rupture following sudden blunt trauma. In various studies it is found that 92% of aortic rupture occur at isthmus followed by arch of aorta (4%) followed by ascending

aorta (3%). Descending aorta rupture was seen in 1% cases. Usually, all layers of aorta are involved in aortic transections, which happen transversely with the edges found several centimetres apart.^{1, 2,3,4,5}

The ligamentum arteriosum, the left main stem bronchus and the paired intercostal arteries limit movement of the proximal descending aorta. However, experiments have shown that displacement of the aorta in either the cranial or caudal direction can result in traction tears at the isthmus.^{1, 2,3,4,5}

According to a different idea, the aorta bursts, and tears at its weakest spot when hydrostatic pressure suddenly increases at impact due to deceleration force.^{1, 2,3,4,5}

One of the recently done a study in USA and Canada was shows that 7000-8000 victims die every year in automobile related trauma and leading cause was blunt traumatic aortic rupture⁶.

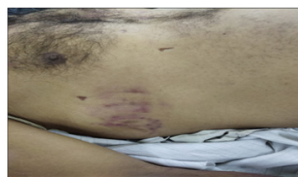


Figure 1

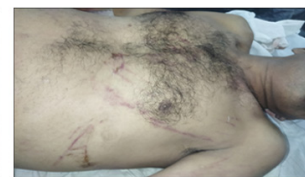

Figure 2

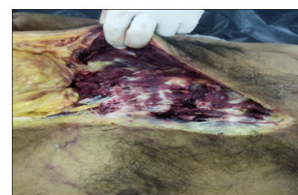

Figure 3

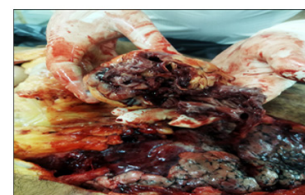

Figure 4

Conclusion

One of the most serious and life-threatening conditions is aortic injury. It is the second largest cause of death worldwide, after head injuries. The most common cause is blunt trauma, but penetrating injuries may also be responsible. Significant mechanisms for aortic trauma damage included rapid acceleration and deceleration. Significant deceleration occurs in head-on collisions or lateral impact. The greatest risk involves frontal or side impacts.

Financial support and sponsorship: Nil

Conflicts of interest: There are no conflicts of interest

Informed consent: Not applicable as it is medicolegal autopsy based case where subject confidentiality was maintained.

Ethical clearance: taken from institutional ethical committee

Reference

1. Harmouche M, Slimani EK, Heraudeau A, Verhoye JP. Blunt traumatic aortic rupture of the proximal ascending aorta repaired by resection and direct anastomosis. *Interactive cardiovascular and thoracic surgery*. 2013 Oct 1;17(4):739-40.
2. Benjamin MM, Roberts WC. Fatal aortic rupture from nonpenetrating chest trauma. In *Baylor University Medical Center Proceedings* 2012 Apr 1 (Vol. 25, No. 2, pp. 121-123). Taylor & Francis.
3. Penn JL, Martindale JL, Milne LW, Marill KA. Aortic dissection associated with blunt chest trauma diagnosed by elevated D-dimer. *International Journal of Surgery Case Reports*. 2015 Jan 1;10:76-9.
4. Mosquera VX, Marini M, Guías D, Cao I, Muñiz J, Herrera-Noreña JM, López-Pérez JM, Cuenca JJ. Minimal traumatic aortic injuries: meaning and natural history. *Interactive cardiovascular and thoracic surgery*. 2012 Jun 1;14(6):773-8.
5. Hagan PG, Nienaber CA, Isselbacher EM, Bruckman D, Karavite DJ, Russman PL, Evangelista A, Fattori R, Suzuki T, Oh JK, Moore AG. The International Registry of Acute Aortic Dissection (IRAD): new insights into an old disease. *Jama*. 2000 Feb 16;283(7):897-903.
6. Richens D, Field M, Neale M, Oakley C. The mechanism of injury in blunt traumatic rupture of the aorta. *European Journal of Cardio-Thoracic Surgery*. 2002 Feb 1;21(2):288-93.