

# Isolating Liver abnormalities in CT Scan Images Using Enhancement Based Technique

Rabab Saadoon Abdoon<sup>1</sup>, Zahraa Ali Khudair<sup>1</sup>

<sup>1</sup>Department of Physics, College of Science, University of Babylon, Hilla, Iraq

## Abstract

One of the most dangerous diseases that causes death is liver cancer. As faster as detection of liver tumors and other abnormalities, as chances of survival will be increased. There are many modalities of medical scanning such as CT scan can be adopted for early detecting of the presence of any liver abnormality. In this study many CT scan liver images were adopted to investigate the robust performance of the proposed segmentation method. The proposed technique is an enhancement histogram based method employed here for segmentation purpose. The results of the presented technique showed the success of the technique in isolating and extracting the abnormal regions adequately. As well as, the implemented segmentation technique succeeded to extract the approximated whole liver regions according to the consultation of the radiologist. The processed technique was evaluated by calculating its accuracy to extract abnormal regions and it was 100%, whereas for extracting the whole liver regions the accuracy was 90%. In this study, the percent relative surface area of the abnormal regions were calculated as well.

**Keywords:** *contrast adjusting, liver cancer, segmentation, enhancement, morphological operations.*

## Introduction

Liver locates at the upper right side of the human abdomen and it occupies the largest area among the various organs within the abdomen image <sup>1</sup>. It is well known that liver is built up of different types of cells, all types of liver cells are susceptible to many types of tumors, cancerous or noncancerous <sup>2</sup>. Computed Tomography, CT and many other modalities of medical imaging represent essential tools for fast diagnosis of the presence of any abnormal case within any member or organ of the body including the liver <sup>3</sup>. Identifying liver on CT abdominal image is a challenging task due to the similarity of the intensity of other organs with the liver's intensity, and this makes the segmentation process more difficult <sup>1</sup>. According to the importance of detecting tumors and other abnormalities of liver, many researchers dedicated their efforts to process the medical images of liver in order to determine the site, area, volume and the shape of the abnormal regions as well as any other meaningful information to facilitate accurate diagnosis. One of the most principal processes,

is segmenting of the medical images to isolate or extract the abnormal regions. Several segmentation techniques were presented to handle this task, and many of these techniques gave promising findings <sup>(3, 4)</sup>. Some researchers adopted and implemented clustering algorithms to segment medical images, while others proposed texture based methods and other researchers implemented neural network approaches and many other methods, see for examples <sup>(1, 3, 5-11)</sup>. In this work a simple and accurate technique is presented. The proposed technique is an enhancement histogram based method employed here for segmentation purpose to isolate and extract liver abnormalities.

## Enhancement Contrast based Technique

The objective of enhancement techniques of digital images is to improve the quality or the characteristics of the processed images, in such a way that, the resultant images become better than the original ones if they compared according to a specific criterion <sup>12</sup>. When the contents of the processed image are difficult to identify, contrast adjustment becomes essential, especially due to its ability to enhance the details in dark and bright regions <sup>13</sup>. There is no general theory of image enhancement. When an image is processed for visual interpretation,

the viewer is the ultimate judge of how well a particular method works<sup>14</sup>. Enhancing an image in spatial domain depending on the image's histogram, which is adopted in this work, is well explained in details in (14-16).

**Experiments Procedure**

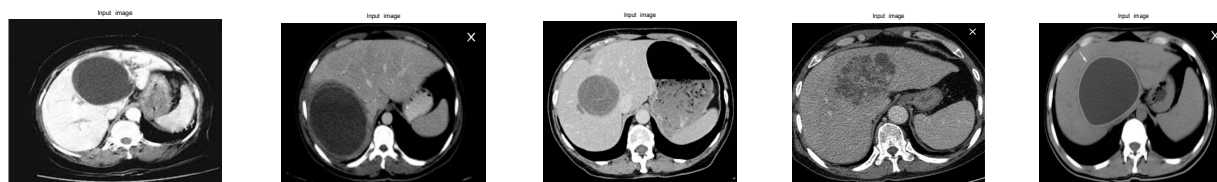The procedure of this work can be summarized as follows:

1. Input liver images.
2. Test many gray level ranges of the input images to be the whole intensity.
3. Select the proper range that differentiate the liver region upon other parts.
4. Utilize different morphological operations to get the liver region only.

5. Repeat steps 2 &3 to differentiate the abnormal regions upon other parts of liver.
6. Use different morphological operations to isolate the abnormal regions only
7. Calculate the surface area of the extracted liver regions as well as the abnormal regions.

**Experimental Images**

Many CT scan liver images were adopted to investigate the performance of the proposed technique, Figure (1) presented five of them as examples. These five images are of (992x866, 1080x731, 1280x1066, 1280x1134 and 1280x858) pixels of size from first image to the fifth one respectively. All the adopted images were acquired from the internet websites. According to the consultation of the radiologist, these images are for patients suffer from Haydatid cyst, Haydatid cyst, tumor, bloody hematoma and Hydro. cyst for the five images from the first to the fifth one respectively.



**Figure (1): Input medical liver images.**

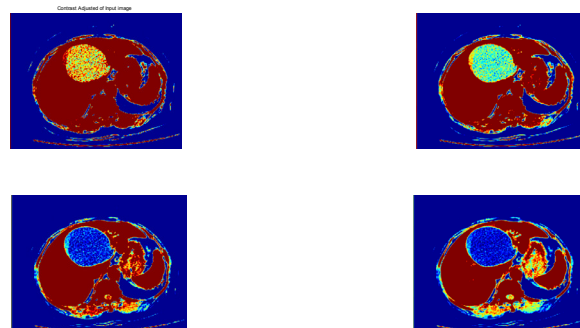
**Experiments and Results**

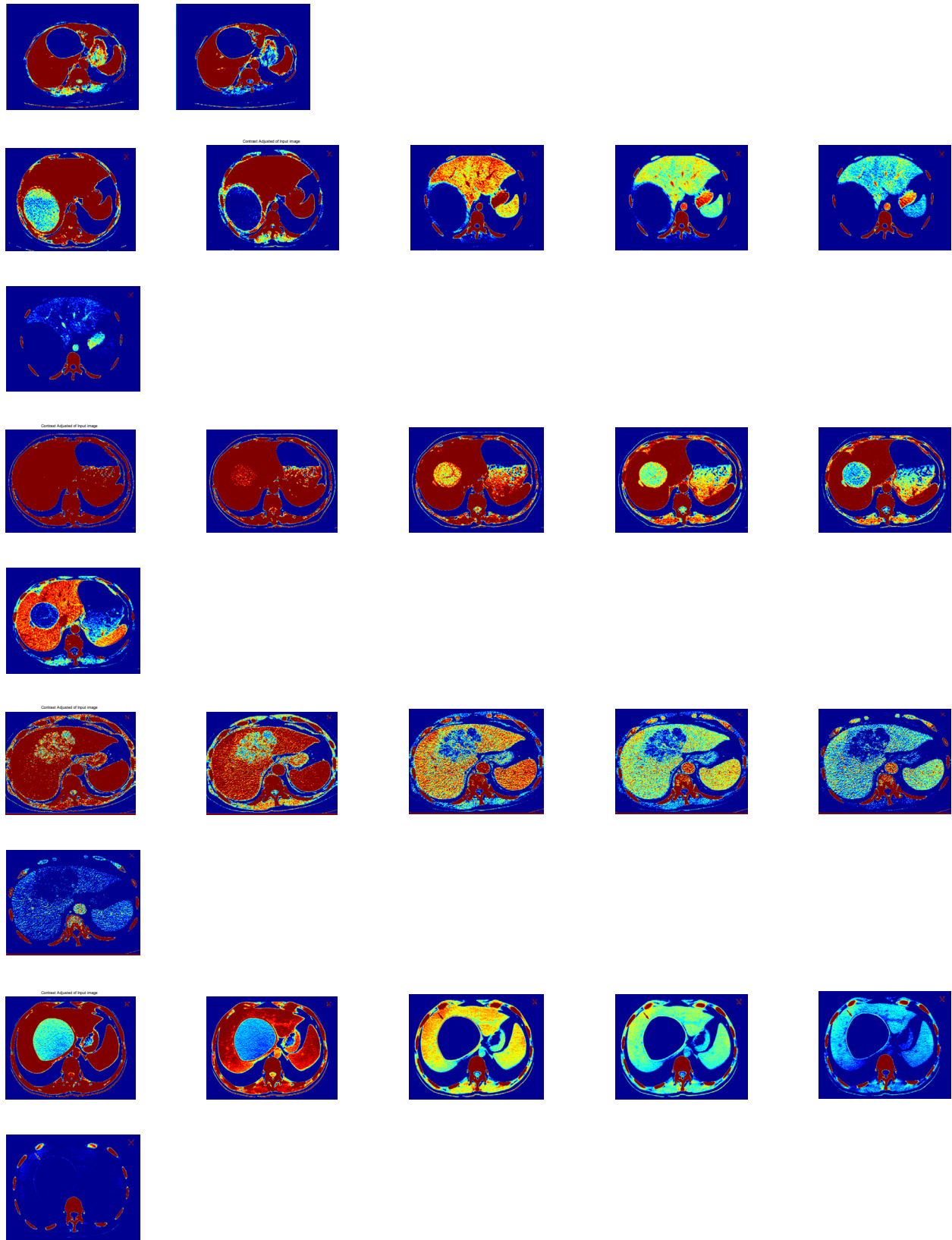
The steps of fulfilling this work are presented as follows:

**Suitable Intensity Ranges**

Many gray level ranges of the input images were tested to be the whole intensity of the experimental images to select the proper range that enable isolating the liver regions and the abnormal regions within the input images. These ranges are ranged from [0.1- 0.3] to [0.5-0.8]. Figure (2) shows samples of the contrast adjusted images

for the five tested images.





**Figure (2): Contrast adjusted images for different selected gray levels for the adopted medical liver images.**

In Figure (2), the contrast adjusted images for different selected gray levels for five liver images from first line to the fifth one to highlight the abnormal regions ones . To extract abnormal regions, it is found that, the ranges  $[(0.2-0.5), (0.1-0.3), (0.3-0.7), (0.2-0.5) \text{ and } (0.2-0.5)]$  for the first four images respectively, were the most proper ranges to highlight liver regions desired regions. While for the whole liver regions isolation, the ranges  $[(0.3-0.6), (0.2-0.3), (0.5-0.8) \text{ and } (0.2-0.4)]$  for the five images respectively are the suitable ranges to highlight the

### Isolating and Extracting of Liver Regions

By adopting the proper gray level rang to be the image whole range and by the aid of the morphological opening process with disk shaped structure elements, as well as implementing area selector, the liver regions could be extracted. Figure (3) showed the results of this step for four liver CT images. The selected gray level range and the radii of the structure element depend on the processed images and differ from image to another. The approximated extracted live regions are presented in second line, while the third line shows the gray images

of the liver after convoluting the B/W images of second line with the original input images.

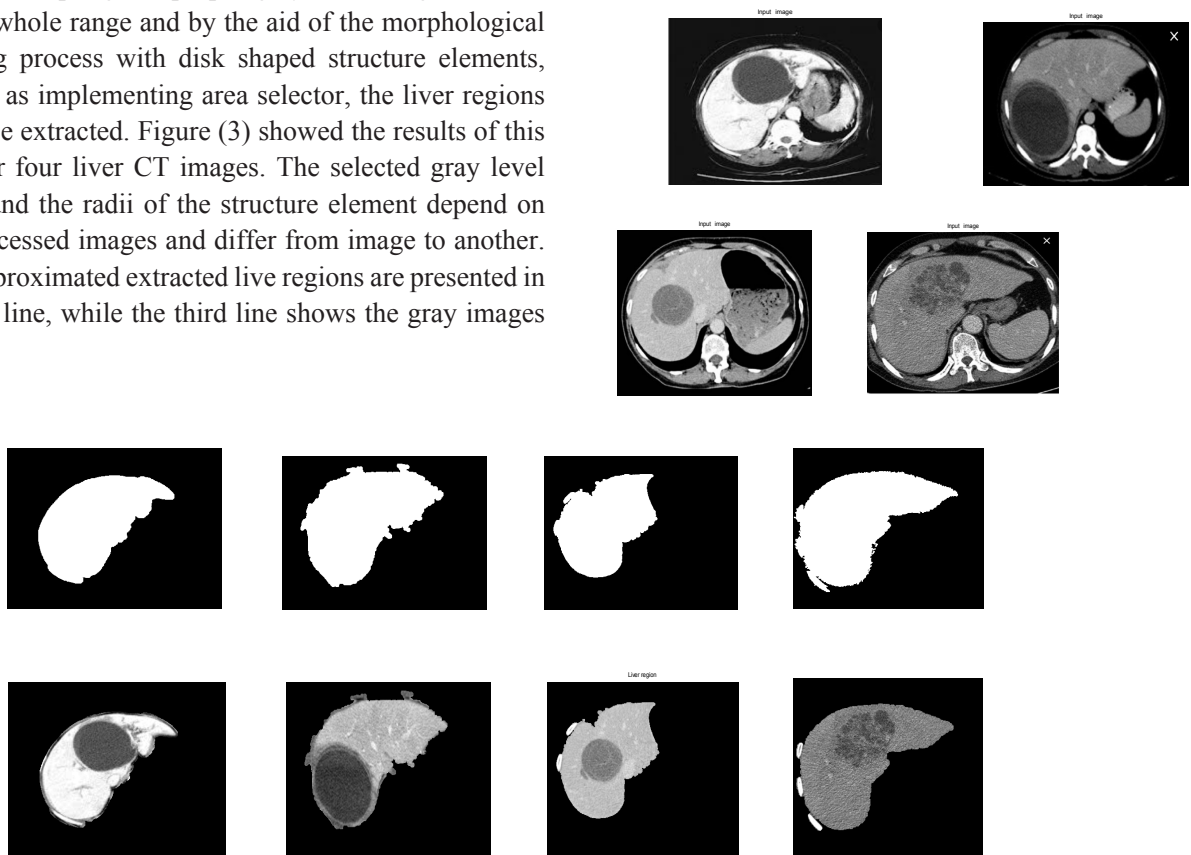


Figure (3): Results of extracting approximated final liver regions for the adopted medical liver images.

### Extracting the Liver Abnormal Regions

From different gray level ranges, the suitable ones that enable isolating abnormalities upon other liver regions, were adopted to extract the abnormal regions. Opening morphological process and selecting areas function were applied to achieve the extraction process completely. The adopted radius of the structure element depends on the

processed image and it differ from image to another. Figure (4) presents the results of this step, the refined extracted abnormal regions are shown in the third line.



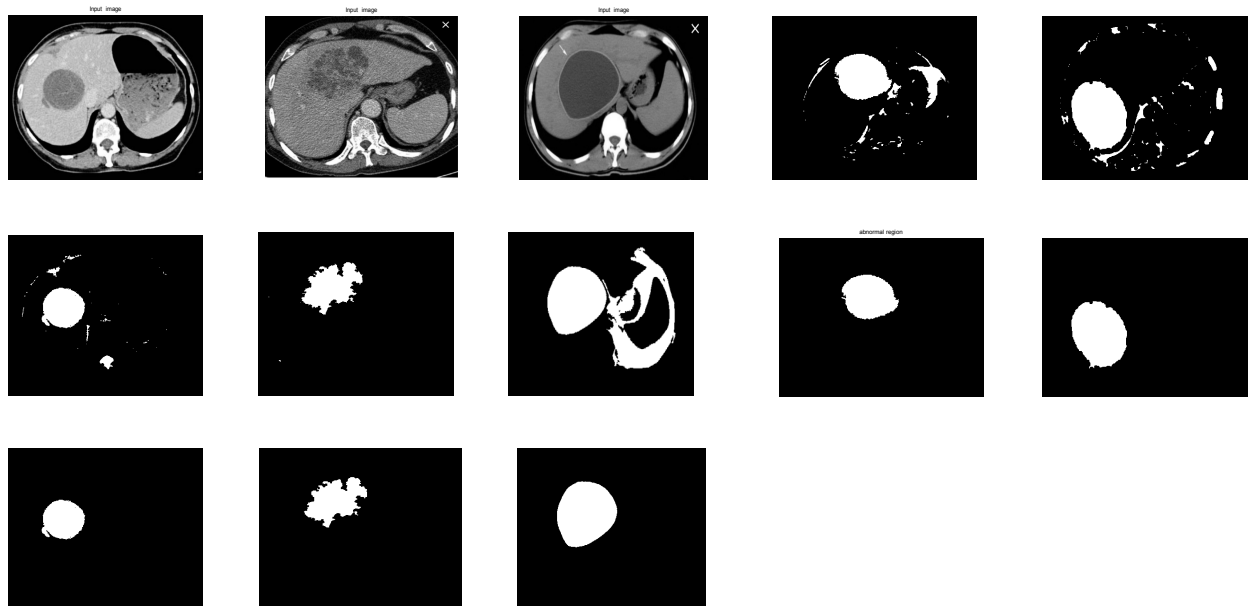


Figure (4): Results of extracting refined abnormal regions for the adopted medical liver images.

The surface area (white pixels in B/W image) of the approximated extracted liver regions and the surface area of the refined extracted abnormal regions were calculated, as well as the percent relative surface area of the extracted abnormal regions with respect to the surface area of the extracted live regions was calculated also and presented in Table (1). The proposed segmentation

technique was evaluated for its accuracy by calculating the number of succeeded cases to the total number of the processed images, and it was found that the accuracy equals 100% for extracting the abnormal regions and the accuracy equals 90% for extracting the whole liver regions without extra portions of other organs within the abdominal.

Table (1): Calculated surface area of the extracted approximated liver regions and the refined extracted abnormal regions as well as the percent relative surface area of the extracted abnormal regions.

Image	Image1	Image2	Image3	Image4	Image5
Surface area of extracted liver region (pixel)	164833	247427	332568	488607	*
Surface area of extracted abnormal regions (pixel)	49178	67002	54861	78723	110048
Percent relative surface area of extracted abnormal regions (%)	29.8400	27.0795	16.4962	16.1117	*
*Liver region of this image could not extract without extra portions of other organs.					

## Conclusion

It is known that CT scan can be adopted for early detecting liver abnormalities. In this study, many CT scan liver images were adopted to investigate the robust performance of the proposed technique which is an enhancement histogram based method employed here for segmentation purpose. The results showed the success of the presented technique in isolating and extracting the abnormal regions adequately. As well as, the proposed segmentation technique succeeded to extract the approximated whole liver regions. The processed technique was evaluated by calculating its accuracy to extract abnormal regions and it was 100%, whereas for extracting the whole liver regions the accuracy was 90%. In this study, the percent relative surface area of the abnormal regions were calculated as well.

**Financial Disclosure:** There is no financial disclosure.

**Conflict of Interest:** None to declare.

**Ethical Clearance:** All experimental protocols were approved under College of Science, University of Babylon and all experiments were carried out in accordance with approved guidelines.

## References

1. Thayalini P. Medical Image Processing Methodology for Liver Tumor Diagnosis, *International Journal on Soft Computing (IJSC)*, November 2017; 8( 3/4) .
2. Wiederkehr JC, Coelho IM, Avilla SG, Wiederkehr BA, Wiederkehr HA, *Hepatic Surgery: Liver Tumors in Infancy*. 2013.
3. Rabab S, Khudair OS. Extracting of Liver Abnormalities and Tumors in Medical Magnetic Resonance Imaging and Computed Tomography Scan Images. *Journal of Advanced Microscopy Research*. 2018; 13: 430-450.
4. Worth AJ, Makris N, Caviness VS, Kennedy DN. Neuroanatomical Segmentation in MRI: Technological Objectives” Center for Morphometric Analysis, General Hospital-East, Charlestown, USA, 2000.
5. John EK , Newman FD , Johnson TK , Kirch DL . Abdominal Organ Segmentation Using Texture Transforms and a Hopfield Neural Network. *IEEE Transactions on Medical Imaging*, 1999;18(7):640-648.
6. Lee CC, Chung PC , Tsai HM . Identifying Abdominal organs from CT image series using a Multimodule Contextual Neural network and Spatial Fuzzy rules. *IEEE Transactions on Information Technology in Biomedicine*, 2003; 7(3) 208-217.
7. Mala K , Sadasivam V , Alagappan S. “Neural Network based Texture Analysis of Liver Tumour from Computed Tomography Images,” *World Academy of Science, Engineering and Technology International Journal of Medical, Health, Biomedical, Bioengineering and Pharmaceutical Engineering* 2008; 2(1).
8. Campadelli P, Casiraghi E, Esposito A. Liver segmentation from computed tomography scans: a survey and a new algorithm. *Artif Intell Med* . 2009;45(2-3):185-196.
9. Zayane O , Jouini1 B , Mahjoub MA. Automatic liver segmentation method in CT images. *Canadian Journal on Image Processing & Computer Vision*, 2011;2(8).
10. Jayanthi M , B Kanmani. “Extracting the Liver and Tumor from Abdominal CT Images.” *Signal and Image Processing (ICSIP)*, 2014 Fifth International Conference on. IEEE, 2014.
11. Rabab S Abdoon , Khudair OS. Employing Histogram Equalization Enhancement Technique to Segment Different Medical Images of Three Organs. *Journal of Advanced Microscopy Research* 2018;13: 494-502.
12. Tang J , Peli E , Acton S . “Image enhancement using a contrast measure in the compressed domain”,*IEEE Signal Process. Lett.*, Oct ,2003;10( 10): 289-292.
13. Ching C, Manh H. X-Ray Enhancement Based on Component Attenuation, Contrast Adjustment, and Image Fusion”, *IEEE Transactions on Image Processing*. 2019; 28 (1 ): 127-141.
14. Gonzalez RC, Woods RE. *Digital Image Processing*”, Prentice Hall, 2002.
15. Gonzalez RC, Woods R. Eddins SL., “*Digital Image Processing Using MATLAB*”, Pearson Prentice-Hall, 2004.
16. Rabab S, Abood LK, Ali SM.. *Adaptive Techniques for Brain Tumor Detection in MRI*, Lap LAMBERT AcademicPublishing, Germany, 2015.