

Histological Changes in Liver Tissue Resulting from Hydatid Cyst Infection: Comparison between Sheep and Cattle in Iraq

Intidhar Mohammed Mnati¹, Baydaa Hussain Mutlak¹, Noora Dhyaaldain Abed²

¹College of Education for Pure Sciences (Ibn Al-Haithum), Baghdad University,

²College of Education for Pure Sciences, Diyala University

Abstract

Hydatidosis is one of the most common parasitic zoonosis diseases not only in Iraq but throughout the world. Liver infected with hydatid cysts were randomly collected from 15 sheep and 18 cows of different ages and sexes during the period extended from September 2018 to December 2018. This study was aimed to provide insight on the histological changes of liver associated with *E. granulosus* and to compare the changes of liver tissue between sheep and cattle. Samples were collected from private (individual) butchers' places at Diyala province in Iraq. Livers had been transferred to Zoology Laboratory in Department of Biology in College of Education for Pure Sciences in Diyala University. Specimens from infected livers were immediately taken and fixed in 10 % formalin. Then the routine histological sections were done. The results showed that there were many histological changes resulting from infection with hydatid cysts infection including infiltration of inflammatory cells, necrosis, degeneration of liver tissue, fibrosis, fibrosis around portal veins, congestion of portal vein, increase in bile duct numbers, maladjustment of hepatic cords. A comparison between the histological changes of sheep and cattle showed the same histological changes, with a difference in the severity of these changes as they were more severe and developed in the livers of cattle than in sheep.

Key words: hydatid cyst, histological changes, cattle, sheep

Introduction

Hydatidosis is one of the most common parasitic zoonosis diseases not only in Iraq but throughout the world. The disease considers as a major threat to public health in many regions of the world, especially in developing countries, as well as large economic losses resulting from the infection of livestock ⁵. Despite the variety rates of infection in different countries, the incidence of this disease in both human beings and economic animals constitute a significant importance and may be a potential factor for new infection ¹⁰.

The disease caused by the larval stage of the small tapeworm *Echinococcus granulosus* (family *Taeniidae*). This parasite lives as a small intestinal cestode of dogs and occasionally other carnivores while their larval form lives in domestic animals and accidentally in man ¹¹. As the symptoms of this disease has been slowly developing, the disease is only detected after the infection has been exacerbated. The primary location of this cyst is the liver and lung but it could have located in other organs like

kidneys, bone marrow, spleen, heart and brain etc. ¹³.

Most of domestic animals represents as the main source of food for human in Iraqi populations and they have been used as a source both milk and meat. Liver is a vital organ as it characterized by multiple functions categorized broadly as synthetic, catabolic, detoxifying, secretory and excretory ⁴. Most of domestic animals represents as the main source of food for human in Iraqi populations and they have been used as a source both milk and meat. Liver is a vital organ as it characterized by its multiple functions including synthetic, catabolic, detoxifying, secretory and excretory in addition to use it as food ⁹. As other organs, the liver may have affected by a variety of pathogens causes resulting in huge economic losses either directly through throw it ¹⁴ or indirectly by effect on animal production ^(9, 14). The examination of histology changes provides highlights into interactions between pathogens and their host that it ¹⁶. This study was aimed to provide insight on the histological changes of liver associated with *E. granulosus* and to compare

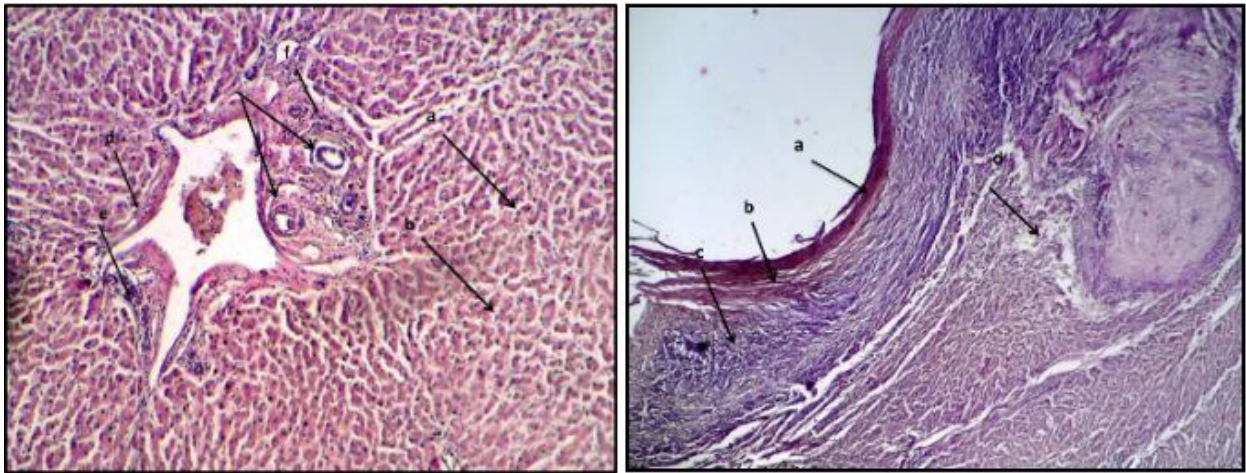
the changes of liver tissue between sheep and cattle.

Materials and Method

Liver infected with hydatid cysts were randomly collected from 15 sheep and 18 cattle of different ages and sexes during the period extended from September 2018 to December 2018. Samples were collected from private (individual) butchers' places at Diyala province in Iraq. Livers had been transferred to Zoology Laboratory in Department of Biology in College of

Education for Pure Sciences in Diyala University and careful visual examination and identification of hydatid cysts was carried out. Specimens from infected livers were immediately taken and fixed in 10 % formalin. After fixation, the specimens were cut into about 1cm pieces, trimmed, washed, dehydrated in graduated concentrations of ethyl alcohol, then cleared in xylol and embedded in paraffin. Then the samples were sectioned at 4-6 microns and stained with hematoxylin and eosin stain for general histological examination.

Results



Th

The histological examination in the present study obtained that there are many hydatid cysts embedded in liver tissue in 7 of examined livers of sheep and 5 of examined livers of cows resulting in histological changes in infected livers of both cattle and sheep. Both these animals have the same changes with deference in severity. The changes included as shows in Figures, the germinal layer of the cyst surrounded with fibrosis and infiltration of lymphocyte cells and other inflammation cells and there is a necrosis in the tissue (Figure1), in addition of necrosis and infiltration of inflammatory cells around the bile ducts and blood sinusoids, there is propagation in bile duct numbers and expansion of blood sinusoids(Figure2)

Fig.1: Sheep liver: a. germinal layer of the hydatid cyst, b. fibrosis, c. infiltration of lymphocytes , d. necrosis (4x)

Fig.2 sheep liver: a. and b. necrosis, c. propagation in bile duct numbers, d. expansion of blood sinusoids, e and f, infiltration of lymphocytes(10x)

In Figure 3 and 4 there is clearly occurrence of fibrosis and maladjustment of hepatic cords as well as heavy infiltration of inflammation cells, in addition to necrosis in both figures.

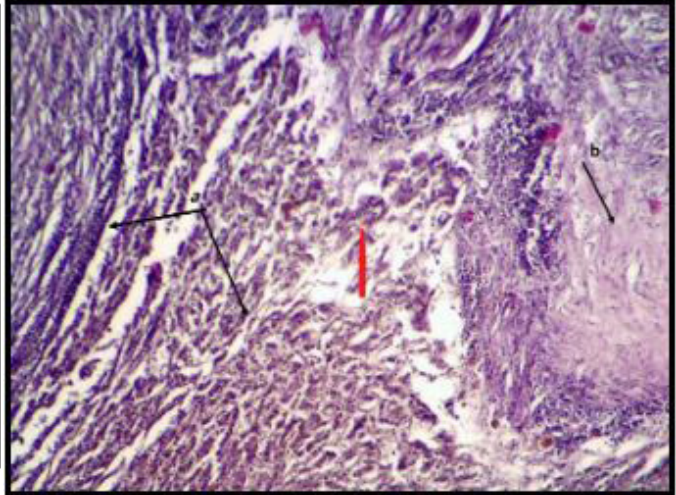
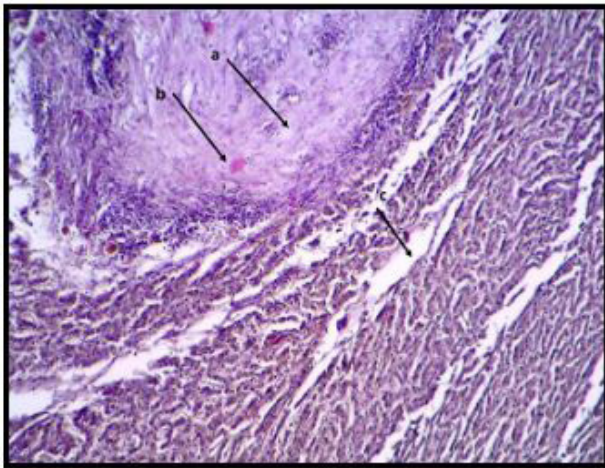
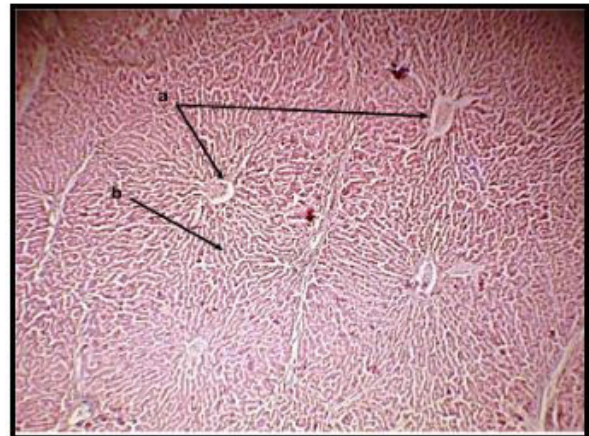
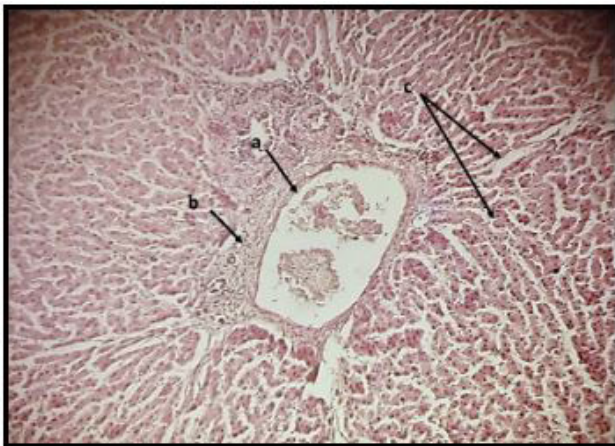


Fig3:sheep liver: a. maladjustment of hepatic cords, b. fibrosis of the connective fibers (10x)

Fig4:sheep liver a. fibrosis, b. spot of hemorrhage , c. maladjustment of hepatic cords(10x)



Congestion and expansion of portal vein and infiltration of lymphocyte around portal vein in addition to expansion of blood sinusoids as shows in Figure 5. The central veins expended and there is a congestion in these veins with increase of connective tissue around the portal and central veins (Figure 6).

Fig5: cow liver a Congestion and expansion of portal vein, b. infiltration of lymphocyte around portal vein, c. expansion of blood sinusoids.(10x)

Fig. 6: cow liver: The expansion and congestion in central veins, b. increase of connective tissue around the portal and central veins.(4x)

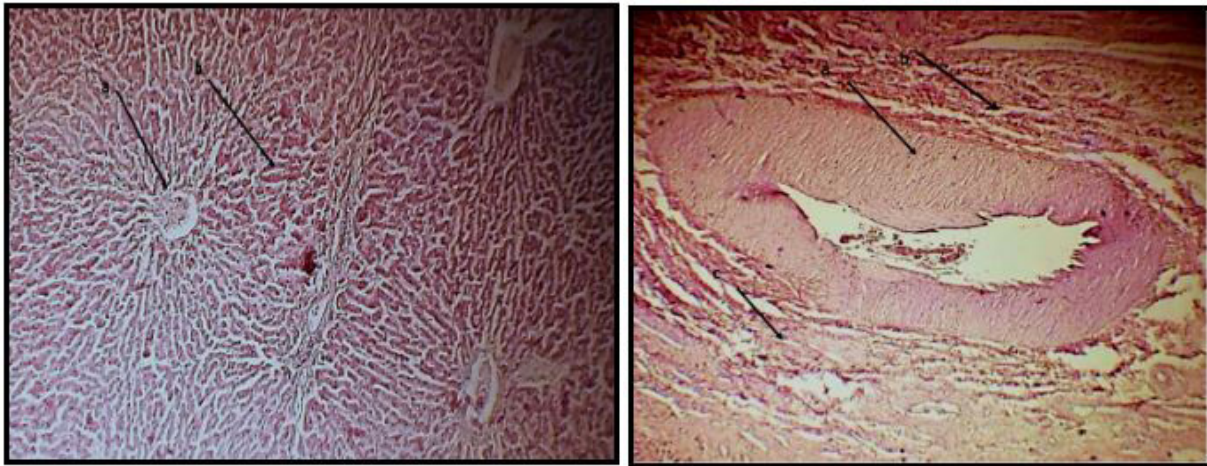


Figure 7: liver: a. expansion and congestion of portal vein, b. infiltration of lymphocyte cells(10x)

Figure 8: liver: a. expansion of portal vein and increase of thickness wall of portal vein, b. lymphocytes, c. fibrosis around portal vein (10x)

Histological changes included also, Necrosis, fibrosis, infiltration of inflammatory cell, cirrhosis in Figure(9). Necrosis, fibrosis, inflammatory cell in portal area, maladjustment of hepatic cords

Both Figures(11) and (12) obtained fibrosis around portal veins and infiltration of inflammatory cells and congestion of portal vein and necrosis, it can be seen the increase in bile duct numbers and the layer of hydatid cyst surrounded with fibrosis in Figure(12). A comparison between the histological changes of sheep and cattle showed the same histological changes, with a difference in the severity of these changes as they were more severe and developed in the livers of cattle than in sheep.

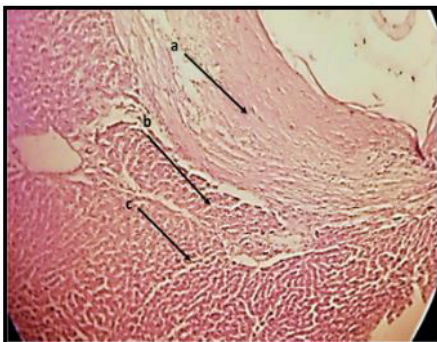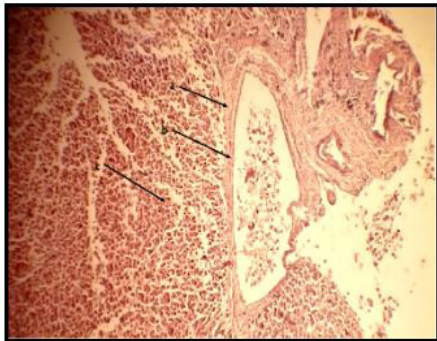


Figure 9: cow liver: a. fibrosis, b. expansion in portal vein, c. infiltration of inflammatory cell (10x) **Figure10:cow liver: a. fibrosis, b. inflammatory cell around portal area, c. maladjustment of hepatic cords (10x)**

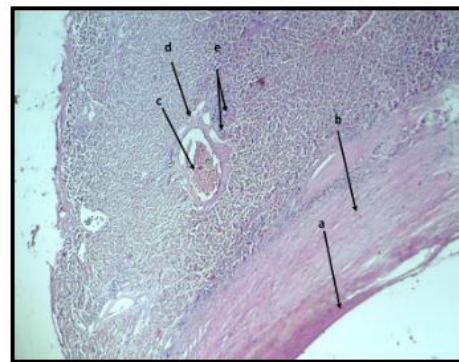


Figure11:cow liver: a. necrosis, b infiltration of inflammatory cells, c. congestion , d fibrosis(10x) **Figure12:cow liver: a. hydatid cyst wall, b. fibrosis, c. congestion ,d. fibrosis around portal vein, e. bile ducts (4x)**

Discussion

Hydatid cysts may arise anywhere in the intermediate host body (animals and human) but it mostly arise in

liver as hepatic capillary network forms the first capillary filter for circulating hexacanth embryos¹, they slowly develop to the hydatid cyst in this organ¹⁸. So, the disease remains asymptomatic in intermediate animal hosts until they reach to suitable volume to initiate the symptoms⁸. Although, there are many histological changes resulting from hydatid cysts infection. The present results of this study obtained that they are many changes in liver tissue and these changes including: infiltration of inflammatory cells, necrosis, degeneration of liver tissue, fibrosis, fibrosis around portal veins, congestion of portal vein, increase in bile duct numbers, maladjustment of hepatic cords, These results agree with many previous studies (2,4,12) as they reported that the hydatid cysts infection resulting in many histological changes in any infected organ.

The enlarged cysts pressed on the hepatocytes and congested the portal veins in addition to maladjustment of hepatic cords caused as a result of the pressure resulting from these cysts and this agree with⁶ who recorded that the experimentally infected mice have histopathological changes including hepatocytes and congested the portal veins in addition to maladjustment of hepatic cords resulting from the pressure of enlarged cysts. The same authors obtained that the reactions, such as lymphocytes infiltration and fibrosis capsules were occurred for the final cleanup of the residual debris of cysts⁶. These results as well as to the results that recorded by³ concur with the present study that revealed that fibrosis was occurred heavily in cattle liver tissue compare with sheep liver tissue as the age of slaughtered animals (the mean cattle age was one year while the mean sheep age was five months). The difference in age between cattle and sheep gives the time for the development and growing of the cysts in the cows according to the fact that this process is slowly. The fibrous tissue developed as a host's reaction to the parasite inflammatory effect, initiated in the early development stages of the cyst and the intensity of this reaction effect on the cystic development, if there is a heavily reaction it will lead to degeneration or death of the parasite while a moderate reaction allows the development of a viable cyst¹⁵. The present study compared between the liver's histological changes in both of sheep and cattle infected with hydatid cyst. In both, the reaction of the host to the presence of hydatid cyst referred to very clear chronic inflammatory reaction characterized by fibrosis associated with lymphocytic reaction and congestion, centrally with areas of necrosis and this agree with³

There was infiltration of lymphocytes recorded in the present study in both of sheep and cattle liver this due to inflammatory reaction of host –parasite interaction as¹⁷ study suggest the impact of the host's susceptibility on the composition of T lymphocytes which are locally activated in response to hydatid infection of the liver.

Increase in the number of bile ducts and thicken in their wall and expand their cavity occur in the liver in present study. This agree with⁷ who obtained that a large hydatid cyst caused compression on the bile duct bifurcation with proximal bile duct dilatation. In the hepatic parenchyma a slight hemorrhage and mild hepatocellular degeneration occurred in the present study and were in accordance with the findings of an earlier worker,¹⁸. These changes may due to the pressure of hydatid cyst that that cause in destruction of hepatocells.

This study concludes that the hydatid cyst infection result in many histopathological changes in both of cattle and sheep with difference in severity tend to cattle.

Financial Disclosure: There is no financial disclosure.

Conflict of Interest: None to declare.

Ethical Clearance: All experimental protocols were approved under the Baghdad University, Iraq and all experiments were carried out in accordance with approved guidelines.

References

1. Abdel Aziz R , El Meghanawy R A , Ibrahim FFM , El Zahaby DAI. Occurance of hydratic cyst in camels (*Camelus dromedarius*) and their effect on meat quality Egyptian Journal of Chemistry and Environmental, 2016;2 (1):48-6
2. Ahmedullah F , M Akbor, M G Haider, M M Hossain, MAHNA Khan, M I Hossain , IS Shanta. Pathological investigation of liver of the slaughtered buffaloes in barisal district. Bangladesh Journal of Veterinary Medicine, 2007; 5 (1 and 2): 81-85
3. AL-Azizzi SA, Ali MA, Da'aj SA, Kadhim MS. Histocomparative study of liver and lung of donkey and sheep infected with hydatid cyst in Basrah city. Journal of International Academic research for Multidisciplinary, 2016;4(3):298-306.
4. Borai MGE, Nagi AA, Gab-Allah MS, El Mashad

- A I, Moustafa, SA. Comparative pathological studies on parasitic affections of liver in farm animals. *Benha Veterinary Medical Journal*, 2013;25 (2):284-295.
5. Chalechale A, Hashemnia M, Rezaei F, Sayadpour M. *Echinococcus granulosus* in humans associated with disease incidence in domestic animals in Kermanshah, west of Iran. *Journal of Parasitic Diseases*, 2016;40(4): 1322–1329.
 6. Chen X,Zhang R, Aji T, Shao MY, Chen Y, Wen H. Novel Interventional Management of Hepatic Hydatid Cyst with Nanosecond Pulses on Experimental Mouse Model. *Scientific Reports*, 2017;7.
 7. Colle I, Van Vlierberghe H, Brenard R, Troisi R, de Hemptinne B, Navez B, De Coninck S, De Vos M. Biliary complication of large *Echinococcus granulosus* cysts, reports of 2 cases and review of the literature. *Acta Clinica Belgica*, 2002; 57-6.
 8. Eckert J, Deplazes P, Craig PS, Gemmell MA, Heath D ,et al . *Echinococcosis* in animals: clinical aspects, diagnosis and treatment. In: Eckert J, Gemmell MA, Meslin FX, Pawlowski Z (eds.) WHO/OIE manual on *Echinococcosis* in humans and animals: a public health problem of global concern, Paris: 2001;72–99
 9. Ghebremariam MK, Debesai MG, Sanjay D, Basharat AP. Hydatidosis as a major cause of liver condemnation among parasitic diseases in goats and sheep in Keren slaughterhouse, Anseba zone, Eritrea. *Veterinary World* 2014;7(4): 266-270.
 10. Gholami S, Tanzifi A, Sharif M, Daryani A, Rahimi M, Mirshafiee S, Sarvi S. Demographic aspects of human hydatidosis in Iranian general population based on serology: A systematic review and meta-analysis. *Veterinary World*, 2018;11(10): 1385-1396.
 11. Higueta NIA, Brunetti E, McCloskey C. Cystic *Echinococcosis*. *Journal of Clinical Microbiology*, 2016;54 (3):518-523.
 12. Khalaf AKH , Majeed SK. Evaluation of histopathological changes of hydatid cyst on kidney of experimental infected mice. *Basrah Journal of Veterinary Research*, 2018;17:3:621-628.
 13. Liu C, Xu Y,Cadavid-Restrepo AM, Lou Z, Yan H, Li L., Fu B, Gray DJ, Clements AA, Barnes TS, Williams GM, Jia W, McManus DP , Yang Y. Estimating the prevalence of *Echinococcus* in domestic dogs in highly endemic for echinococcosis. *Infectious Diseases of Poverty*, 2018;7:77 doi.org/10.1186/s40249-018-0458-8.
 14. Singh BB, Dhand NK, Ghatak S, Gill J P S. Economic losses due to cystic echinococcosis in India: Need for urgent action to control the disease. *Preventive Veterinary Medicine*, 2014;113(1): 1–12. doi: 10.1016/j.prevetmed.2013.09.007.
 15. Solcan C, Solcan G,Ioniță M, Mitrea IL, Doru V Hristescu, D V. Histological aspects of cystic echinococcosis in goats. *Science of Parasitology*, 2010;11(4):172.-165
 16. Sołtysiak Z, Rokicki J, Kantyka M. Histopathological diagnosis in parasitic diseases. *Annals of Parasitology* 2014; 60(2) :127–131.
 17. Vatankhah A. Immunopathology of hydatid infection in human liver. PhD. Thesis, Doctoral School of Pathological Sciences, Semmelweis University 2016;140
 18. Verma Y, Swamy M. Prevalence and pathology of hydatidosis in buffalo liver. *Buffalo Bulletin*, 2009;28(4):207-211