

Diagnostic Performance of Multiparametric MR Imaging According to the Location of Prostate Cancer

Jihae An¹, Keum Won Kim¹, Jae Young Seo¹, Young Joog Kim¹, Min Jae Yoon¹, Dong Hyun Oh¹

¹Medical doctor, Department of Radiology, Konyang University Hospital, College of Medicine, Daejeon, South Korea

Abstract

Background/Objectives: Most prostate cancers occur in the peripheral zone (PZ) of prostate and a few in the transition zone (TZ). We compared MRI findings and clinicobiologic findings among PZ, TZ and PZ+TZ prostate cancers to determine if cancer location is independently associated with outcomes.

Methods/Statistical analysis: A retrospective study was performed of 70 men who underwent multiparametric-MRI prior to radical prostatectomy from 2014.03~2018.02. Fifty-two prostate cancers were included in this study. We investigated the comparison serum-PSA, tumor size, prostate weight, Gleason score, presence of extracapsular extension, ADC value on DWI, PIRADS category and pathologic tumor stage, according to the location of prostate cancer (PZ, TZ, and PZ+TZ prostate cancers), using statistical methods.

Findings: 30/52(58%) were PZ in location, 14/52(27%) were in TZ, and 8/52(15%) were with PZ+TZ prostate cancer. Patients with PZ+TZ cancer presented with large total cancer size ($\geq 1.5\text{cm}$), MRI evidence of presence of extracapsular invasion ($p < 0.001$), seminal vesicle invasion ($p = 0.026$) and lymph node invasion ($p < 0.001$). The mean ADC value was significantly lower in the PZ+TZ cancer (mean ADC 0.455 – 0.83 (median 0.643)) than in PZ (0.4555 – 1.342 (median 0.90)) and TZ cancer (0.579 – 1.211 (median 0.895)) ($p=0.005$). There was no significant difference related to serum PSA (p value 0.065), Gleason score (p value 0.235) between PZ, TZ and PZ+TZ lesion.

Improvements/Applications: PZ+TZ prostate cancer is associated with tumor, ECE, seminal vesicle invasion and low ADC value. So, tumor location should be taken into account in the process of evaluation, and mp-MRI can be a good tool to staging prostate cancer.

Keywords: Prostate gland, Prostate cancer, Prostate MRI, Diffusion weighted imaging, Transition zone, Seminal vesicle

Introduction

Prostate MRI is an important diagnostic method for detecting, locating and staging prostate cancer. Prostate MRI and reporting and data system for prostate cancer have evolved. Among them, multiparametric MRI (MP-MRI) and the PI-RADS classification are the most commonly used and the most accurate diagnosis of prostate cancer these days. MP-MRI is a combination of T2-weighted imaging (T2WI), diffusion weighted

imaging (DWI) and dynamic contrast-enhanced (DCE) MRI and is an accurate imaging modality in the detection, localization and stage of prostate cancer, providing both functional tissue information and anatomical information [1,2,3]. About 80% of prostate cancers occur in the peripheral zone (PZ) and 20% of prostate cancers occur in the transition zone (TZ). Most benign prostatic hyperplasia occurs in the TZ. At peripheral zone, tumor usually show smaller volume but Gleason score has higher than transition zone, so it appears more aggressive features [4]. And tumor extent, extracapsular extension of prostate cancer is associated with poor prognostic factors. And it contribute to positive surgical margins during

Corresponding Author :

Keum Won Kim,

E-mail: radkim14@gmail.com

surgery [5,6]. The presence of extracapsular extension (ECE) of prostate cancer after radical prostatectomy is one of the poor prognostic factors associated with cancer recurrence, cancer progression, and cancer-related mortality [7,8]. ECE is also associated with an increase in prostate-specific antigen (PSA) among prognostic factors, and a surgical margin after prostatectomy [9]. MRI findings of ECE in prostate cancer include bulging contours, irregular lines or spindles protruding out of the capsule, and tumor-capsule contact length greater than 1 cm [10]. Our purpose of this study is to evaluate MP-MRI and kinetic features among cancer location and cancer extent, and correlate with clinicopathologic findings for investigate for diagnostic accuracy of preoperative imaging.

Method

This retrospective study was performed with Institutional Review Board approval and the requirement for obtaining informed patient consent was waived. A total of 74 patients diagnosed with prostate cancer, based on MP-MRI prior to radical prostatectomy at our institution between March 2014 and February 2018 (mean age, 72 years; range, 60 – 87 years), were retrospectively analyzed. Clinical, MRI, and pathologic features were obtained. But 22 men were excluded due to whose MR imaging was low-quality with artifact, or incomplete clinicopathologic factors, or underwent neoadjuvant chemotherapy, or underwent robot-assisted prostatectomy. Of all 74 patients, 22 patients were excluded from this study. Fifty-two patients' data was analyzed. One genitourinary radiologist and 3 pathologists reviewed each case and matched each MRI region one more time after surgery was done. First, by clinicopathologic factors, age, preoperative serum PSA, total cancer size and Gleason score was investigated. The 2nd, MR finding included extracapsular extension, like bulging contour, capsular irregular spindle, neurovascular bundle asymmetry, breach capsule tumor extension and tumor capsule contact length. In addition, lymph node invasion, seminal vesicle invasion and ADC value was investigated.

Philips Intera Achieva 3 T MRI system (Philips Medical Systems, Best, Netherlands) was used. Axial, sagittal and coronal views of T2-weighted MRI images of prostate were obtained, using turbo spin echo (TSE) technique. The parameters were TR/TR/FA = 2500/100/90, FOV = 180 × 180 mm, matrix size = 312 × 306, 1.0 NEX, section thickness = 3 mm, and

intersection gap = 0. For T1-weighted MRI images, the axial T1-weighted 3D dynamic gradient-echo fat-suppressed sequence (e-THRIVE GD) technique was used to obtain one pre-contrast image, along with ten early and delayed contrast-enhanced images, each at a one-minute interval. The parameters were TR/TE/FA = 3.3/1.6/10, FOV = 200 × 200 mm, matrix size = 200 × 199, 1.0 NEX, section thickness = 3.5 mm, intersection gap = 0. DWI-Sense of prostate were obtained. In single shot echo-planar imaging with sense encoding, a b-value of 1000 mm²/s was used. The parameters were TR/TE/FA = 3260/65/90, FOV = 180 × 180 mm, matrix size = 72 × 72, 6.0 NEX, section thickness = 3 mm, and intersection gap = 0. For calculation of ADCs, a region of interest smaller than the lesion was selected, without including necrosis or liquids.

For statistical analysis, Statistical Package for the Social Sciences (SPSS), version 25.0 (SPSS Inc., Chicago, IL, USA) was used. Chi-squared analysis, Mann-Whitney and Kruskal-Wallis tests were respectively used to evaluate differences in clinicopathologic outcomes (age, tumor size, serum PSA, Gleason scores, extracapsular invasion, seminal vesicle invasion, lymph node metastasis) between PZ, TZ and PZ+TZ prostate cancers.

Result and Discussion

A total of 52 patients with prostate cancer consisted of eligible study groups. Table 1 showed 30/52(58%) were PZ in location, 14/52(27%) were in TZ, and 8/52(15%) were with PZ+TZ prostate cancer. Patients with PZ+TZ cancer presented with larger total cancer size (≥ 1.5 cm) than PZ cancer or TZ cancer (p value = 0.008). MR finding included extracapsular extension, like bulging contour, capsular irregular spindle, neurovascular bundle asymmetry, breach capsule tumor extension and tumor capsule contact length greater than 10mm. Patients with TZ cancer were less likely to have extracapsular extension (35% [TZ cancer], 40% [PZ cancer] versus 100% [PZ+TZ cancer], p = 0.006). Patient with TZ cancer were less likely to have seminal vesicle invasion (7% [TZ cancer], 13% [PZ cancer] versus 50% [PZ+TZ cancer], p = 0.026). Patients with PZ+TZ cancer were more likely to MRI evidence of presence of extracapsular invasion (p value = 0.006), seminal vesicle invasion (p = 0.026) and lymph node invasion (p < 0.001) than PZ cancer and TZ cancer. The mean ADC value was significantly lower in the PZ+TZ cancer (mean ADC 0.455 – 0.83 (median 0.643)) than in PZ (0.4555

– 1.342 (median 0.90)) and TZ cancer (0.579 – 1.211 (median 0.895)) (p=0.005). There was no significant difference related to serum PSA (p value = 0.065) and Gleason score (p value = 0.235) between PZ, TZ and PZ+TZ lesion. Figure 1 case was 73-years-old man with transition zone prostate cancer with extracapsular extension. Serum PSA was measured 33.84ng/ml. T2 weighted image showed enlarged transition zone and low signal intensity mass lesion on T2 weighted image, similar to benign prostatic hyperplasia. But, diffusion weighted image showed moderate water restriction and low ADC at transition zone than normal-appearing tissue, suggestive of transition zone prostate cancer. Also, T2 weighted image showed irregular bulging contour, capsular irregular spindle, showing positive extracapsular extension. Gross pathology showed transition zone prostate cancer with extracapsular

extension (Gleason score 8). Figure 2 case was 66-years-old man with left peripheral zone prostate cancer, organ confined cancer. Diffusion weighted image shows focal ovoid water restriction lesion at left peripheral zone and T2 weighted image showed no extracapsular extension. Figure 3 case was 73-years-old man with both peripheral zone and transition zone prostate cancer with extracapsular extension. Serum PSA was measured 48.7ng/ml. The diffusion weighted image (b=1000mm²/s) shows heterogeneously high signal intensity at both peripheral zone and transition zone and water restriction. The ADC value of the lesion was 0.455 x 10⁻³ mm²/s. T2 weighted image shows marked bulging contour, capsular irregular spindle, showing extracapsular extension. Gross pathology shows both peripheral zone and transition zone prostate cancer with extracapsular extension (Gleason score 9).

Table 1. Comparison of MRI radiologic findings according to location of prostate cancer

Characteristics	PZ	TZ	PZ + TZ	P value
Number of patients	30	14	8	
Age in years at surgery (median)	58-81 (69.5)	62-79 (70.5)	66-78 (72)	0.656
PSA (ng/mL)				
Median	3.1-43.6 (20.3)	2.5-66.2 (34.4)	5.6-53.3 (29.5)	
≥ 9	21 (41.2%)	7 (13.7%)	2 (3.9%)	0.065
≤ 10	9 (17.6%)	6 (11.8%)	6 (11.8%)	
Gleason score				
6	5 (9.6%)	1 (1.9%)	0 (0%)	
7	21 (40.4%)	12 (23.1%)	5 (9.6%)	0.235
8~10	4 (7.7%)	1 (1.9%)	3 (5.8%)	
Prostate weight				
mean	18-94 (56)	17-116 (66.5)	21-100 (60.5)	
median	12 (30.0%)	6 (15.0%)	2 (5.0%)	0.865
	12 (30.0%)	5 (12.5%)	3 (7.5%)	
Total cancer size				
< 1.5cm	22 (42.3%)	10 (19.2%)	1 (1.9%)	
≥ 1.5cm	8 (15.4%)	4 (7.7%)	7 (13.5%)	0.008
Extracapsular invasion	12 (23.1%)	5 (9.6%)	8 (15.4%)	0.006
Seminal vesicle invasion	4 (7.7%)	1 (1.9%)	4 (7.7%)	0.026
LN invasion	0	0	3 (5.8%)	<0.000
* ADC value	0.455-1.3420 (0.90)	0.579-1.211 (0.895)	0.455-0.83 (0.643)	
1	14 (26.9%)	5 (9.6%)	7 (13.5%)	
2	16 (30.8%)	9 (17.3%)	1 (1.9%)	0.056
Time/SI curve				
2	13 (35.1%)	3 (8.1%)	1 (2.7%)	
3	9 (24.3%)	8 (21.6%)	3 (8.1%)	0.151

* ADC value: ADC values (mean ADC value) (x 10⁻³ mm²/s)

ADC value 1: number of patients with less than mean ADC values

ADC value 2: number of patients with more than mean ADC values

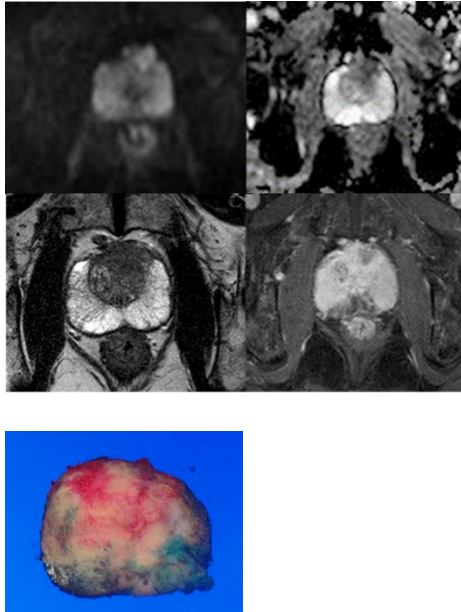


Figure 1. Prostate cancer of transition zone in 74-years old man

(Serum PSA 33.84ng/ml, ADC 0.639, Gleason score 8)

A. The diffusion weighted image (b=1000mm²/s) shows high signal intensity at transition zone.

B. On the ADC map shows water restriction and low ADC than normal-appearing tissue at transition zone, the ADC value of the lesion was 0.639 x 10⁻³ mm²/s .

C. The axial T2 weighted image shows bulging contour, capsular irregular spindle and tumor capsular contact lengths longer than 1cm, positive extracapsular extension.

D. The axial dynamic contrast enhanced image shows heterogeneously enhancing mass with extracapsular extension at transition zone.

E. Gross pathology of specimen shows adenocarcinoma, extracapsular extension at transition zone.

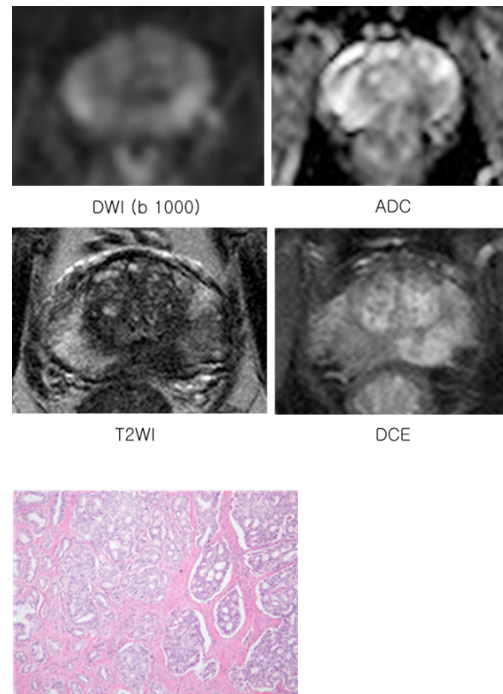


Figure 2. Prostate cancer with left peripheral zone in 66-years-old Ma

(Serum PSA 26.4ng/ml, ADC 0.552, Gleason score 8)

A. The diffusion weighted image (b=1000mm²/s) shows focal high signal intensity at left peripheral zone.

B. On the ADC map shows mild water restriction and low ADC than normal-appearing tissue at left peripheral zone, the ADC value of the lesion was 0.552 x 10⁻³ mm²/s .

C. The axial T2 weighted image shows focal low signal intensity nodule in left peripheral zone without extracapsular extension.

D. The axial dynamic contrast enhanced image shows heterogeneously enhancing nodule without extracapsular extension at transition zone.

E. Histopathology of specimen shows adenocarcinoma, organ confined tumor at left peripheral zone (H 7 E stain, x 200).

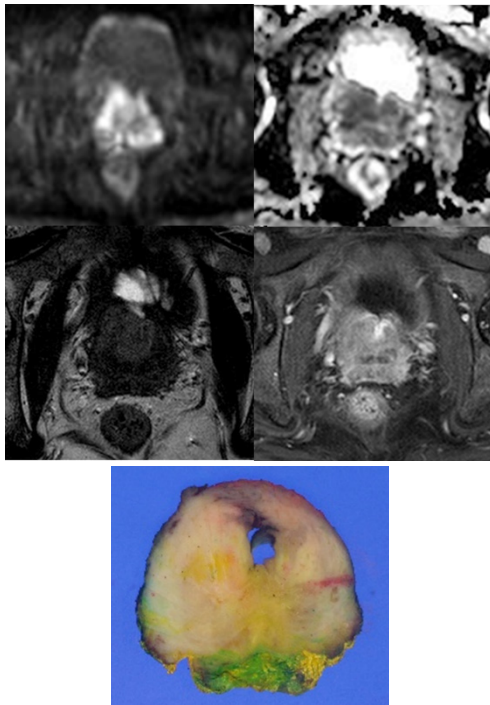


Figure 3. Prostate cancer with peripheral zone and transition zone in 73-years-old Man

(Serum PSA 48.7ng/ml, ADC 0.455, Gleason score 9)

- A. The diffusion weighted image ($b=1000\text{mm}^2/\text{s}$) shows heterogeneously high signal intensity at both peripheral zone and transition zone.
- B. On the ADC map shows water restriction and low ADC than normal-appearing tissue at both transition zone and peripheral zone, the ADC value of the lesion was $0.455 \times 10^{-3} \text{mm}^2/\text{s}$.
- C. The axial T2 weighted image shows marked bulging contour, capsular irregular spindle and tumor capsular contact length was longer than 1cm, positive extracapsular extension.
- D. The axial dynamic contrast enhanced image shows irregular heterogeneously enhancing mass with extracapsular extension at both transition zone and peripheral zones.
- E. Gross pathology of specimen shows adenocarcinoma, extracapsular extension at both peripheral and transition zone.

Conclusion

The transition zone of the prostate is mainly caused by benign prostate hyperplasia, and the incidence of prostate cancer is lower than the peripheral zone. Transition zone prostate cancer is difficult to diagnose even by core needle

prostate biopsy, and it is difficult to differentiate between prostate hyperplasia and prostate cancer of transition zone by transrectal prostate ultrasound or previous conventional prostate MRI. However, MP-MRI scans allowed precise differential diagnosis. The diffusion weighted images would correlate with the pathological moderate and prostate cancer stages of prostate cancer, thus increasing the role of MP-MRI. So, our conclusion is, PZ+TZ prostate cancer is associated with aggressive pathologic features, extracapsular extension, seminal vesicle invasion and low ADC value and can lead to worse outcomes. In the process of predicting patient risk and assessing the patient’s prognosis before prostatectomy, it is necessary to take into account the location of the tumor and the stage of the prostate cancer. MP-MRI can be a good diagnostic tool for detection and staging of prostate cancer. MP-MRI is a beneficial preoperative assessment tool for determining location and extent of prostate cancer.

Ethical Clearance: Not required

Source of Funding: Nil

Conflict of Interest: Nil

References

1. Gupta RT, Brown AF, Silverman RK, Tay KJ, Madden JF, George DJ, et al. Can radiologic staging with multiparametric MRI enhance the accuracy of the Partin tables in predicting organ-confined prostate cancer? *Am J Roentgenol* 2016;207:87-95.
2. Feng TS, Sharif-Afshar AR, Wu J, Li Q, Luthringer D, Saouaf R, et al. Multiparametric MRI improves accuracy of clinical nomograms for predicting extracapsular extension of prostate cancer, *Urology* 2015;86:332-337.
3. Gupta RT, Faridi KF, Singh AA, Passoni NM, Garcia-Reyes K, Madden JF, et al. Comparing 3-T multiparametric MRI and the partin tables to predict organ-confined prostate cancer after radical prostatectomy. *Urol Oncol* 2014;32:1292-1299.
4. Augustin H, Erbersdobler A, Graefen M, Fernandez S, Palisaar J, Huland H, et al. Biochemical recurrence following radical prostatectomy: a comparison between prostate cancers located in different anatomical zones. *The Prostate*. 2003; 55:48–54.
5. Sakai I, Harada K, Kurahashi T, Yamanaka K, Hara I, Miyake H. Analysis of differences in clinicopathological features between prostate cancers located in the transition and peripheral zones. *International journal of urology: official*

- journal of the Japanese Urological Association. 2006; 13:368–372.
6. King CR, Ferrari M, Brooks JD. Prognostic significance of prostate cancer originating from the transition zone. *Urologic oncology*. 2009; 27:592–597.
 7. Wheeler TM, Dillioglulugil O, Kattan MW, Arakawa A, Soh S, Suyama K, et al. Clinical and pathological significance of the level and extent of capsular invasion in clinical stage T1-2 prostate cancer. *Hum pathol* 1998;29:856-862
 8. Hull GW, Rabbani F, Abbas F, Wheeler TM, Tattan MW, Scardino PT. Cancer control with radical prostatectomy alone in 1,000 consecutive patients. *J Urol* 2002;167:528-534
 9. Kausik SJ, Blute ML, Sebo TJ, Leibovich BC, Bergstralh EJ, Slezak J, et al. Prognostic significance of positive surgical margins in patients with extraprostatic carcinoma after radical prostatectomy. *Cancer* 2002; 95:1215-1219.
 10. Matsuoka Y, Ishika J, Tanaka H, Kimura T, Yoshida S, Saito K, et al. Impact of the the prostate imaging reporting and data system, Version 2, on MRI Diagnosis for extracapsular extension of prostate cancer. *AJR* 2017; 209:76—84.